

Orthodontic mini implant: Versatile application for clinical enhancement

Xia CS¹, Ding Y², Kafle D³

¹Professor, ³Resident, Department of Orthodontics, Zhengzhou University, Henan, China, ²Associate Professor, Department of Orthodontics, Beijing University Second Dental Centre, Beijing, China.

Abstract

The use of Orthodontic mini implant (OMI) anchorage is rapidly growing these days. In the recent years it has become a compulsory tool for orthodontist. With the better understanding of the biomechanics not only all kinds of tooth movement is possible with mini implant but orthopedic and orthognathic like effects can also be produced with judicious application of this device. Here we present two cases treated with the help of OMI. The first case needed maximum anchorage due to the degree of crowding and protrusive facial profile. The conventional orthodontic treatment could have produced good result but the ideal result was possible only with the absolute anchorage using mini implant. In the second case there was supra eruption of left maxillary second premolar and first molar. The OMI was used to intrude the supra erupted teeth. The almost impossible tooth movement with conventional orthodontic treatment was possible with the insertion of these implants buccally and palatally, within a period of six months and without any side effects.

Key words: Orthodontic mini implant(OMI), Anchorage, Centre of resistance, Intrusion, Retraction.

During the last two decades, the orthodontic mini implant (OMI) has progressed so much that now it is the everyday armamentarium of an orthodontist. A thorough review of the literature finds that implants for the orthodontic purposes were tried even before Branemark who introduced the dental implant^{1,2}. The screws used for the internal fixation of the fracture sites were used for the orthodontic purposes. Initially stainless steel, then vitallium and now titanium screws are used. However, except few case reports the regular and advanced use of orthodontic mini implants started around the beginning of the new millennium. In 1970 Linkow described the prosthetic implant for orthodontic purpose in a case report³. He presented six cases treated with the help of blade implants. After that regular prosthetic implants were used for the orthodontic anchorage. It undoubtedly served the orthodontic speciality for many years and still are used in some multi disciplinary cases. Those implants were tried even in retro molar area and tuberosity areas for the sake of orthodontic anchorage. However the biggest disadvantage of these implants was their size which confined their placement only in edentulous ridges or retro molar areas.

In the search of small dimension implants and with the idea of surgical screws, the present day orthodontic mini implants were developed. The first purely orthodontic implant dates back to 1983. Greekmore et al inserted surgical screw just below the anterior nasal spine to reduce the anterior deep bite⁴. The implant was made of vitallium and served the orthodontic purpose reducing the deep bite by 6 mm in one year time period. Roberts et al did several animal experiments in the eighties. They had inserted 2mm diameter implants in the femur of the dogs and rabbits with high success rate but similar result were not found in oral cavity⁵. Block and Hoffman in 1995 discovered onplant and used palate as an anchorage source⁶. In 1997 Kanomi used the 1.2mm diameter implant for orthodontic purpose⁷. Since then there have been floods of case reports and clinical researches on mini-implant anchorage. Now there are different designs of orthodontic implants in the market. The continuous modification of the design is still going on and is an on going process. Due to its small dimension (< 2mm in diameter), it can be placed in most of the areas like inter radicular space, mid palatal suture, para-median area of palate, retro molar areas etc. and can be

Correspondence

Dr. Dashrath Kafle, Resident, Department of Orthodontics, Zhengzhou University, Henan, China
E-mail: dashrath07@yahoo.com

used for multiple purposes like de-crowding, orthodontic camouflage, molar distalization, mesialization, intrusion, segmental intrusion, vertical control and treatment of the canted occlusal plane.

Another important advantage of orthodontic implant is its non invasive placement procedure. Flap raising is not needed and most of the implants are drill free (self drilling) which eliminates the extensive surgical procedures and expensive implant kits. They can be inserted under topical anesthesia. The local anesthesia of adjacent teeth is better avoided for the purpose of patient having sensation of pain if implant touches the tooth roots or periodontal ligaments instead of interradicular alveolar bone. This phenomenon is described as bio-feedback mechanism in a recent article by Brumgartel S⁸.

Noteworthy to mention here, the prosthetic implants are invariably osseointegrated. Due to this property, their retention is very stable but one must wait at least 4-6 months before using them for occlusal restoration or orthodontic loading. The orthodontic mini implants used today interestingly are not Osseointegrated rather they are attached with the bone mechanically. Using the property of mechanical stability, the orthodontic implants can be loaded immediately for orthodontic purpose unlike prosthetic implants in which we have to wait at 4-6 months. Initially a light force (50-100 grams) is used, later this force can be increased up to 200-250 grams which is adequate enough for the orthodontic tooth movement. The success rate of these implants is very high but of course proper selection of anatomic site is very important. The success rate of more than 90% is reported in many clinical trials⁹⁻¹². However overnight success of this frequency should not be expected. The learning and experiencing curve is always very steep. OMI can be used to move teeth with absolute preservation of anchorage on regular basis. However implant assisted orthopedic and orthognathic like treatment is now possible^{13,14}. Molar intrusion once considered to be almost impossible tooth movement by conventional orthodontic mechanism, is now easily possible with orthodontic mini implants. Finally the orthodontic implants are far cheaper than dental implants, non-invasive, predictable and reliable. They can be easily removed even with out any kind of anesthesia.

Here we report two cases which were treated in the Department of Orthodontics, Second dental centre of Beijing University and Department of Orthodontics, Zhengzhou University, China.

Case 1

A 23 years old female patient came to the Department of Orthodontics with the chief complaints of irregular

and forward flaring teeth (Fig 1). Her cephalometric analysis (Fig 2) revealed her ANB angle to be 5 degrees with slightly high mandibular plane angle. She was diagnosed to be class II skeletal malocclusion with crowding due to maxillary excess. Her detailed pre treatment cephalometric analysis is shown in Table 1.

Considering her facial profile and degree of crowding, the treatment plan was to extract the upper and lower first premolars. Her anchorage plan was either to put two micro implant in maxilla or use Trans Palatal Arch (TPA) and headgear. After discussing the treatment plan with the patient, she agreed with the first option. The treatment was started with pre-adjusted edgewise appliance, 0.022 × 0.028 inch MBT bracket. Two OMIs were inserted in between upper first molar and second premolar, one on each side. The anterior teeth were retracted by active tie-back from the crimpable hook to the implant (Fig 3). 200gram of force was applied on each side. The post treatment photographs shows improved facial profile and ideal occlusion with class I molar and canine relation, ideal over jet and overbite (Fig 4). Her post treatment cephalometric analysis is shown in Table 1. Total duration of treatment time was 20 months.

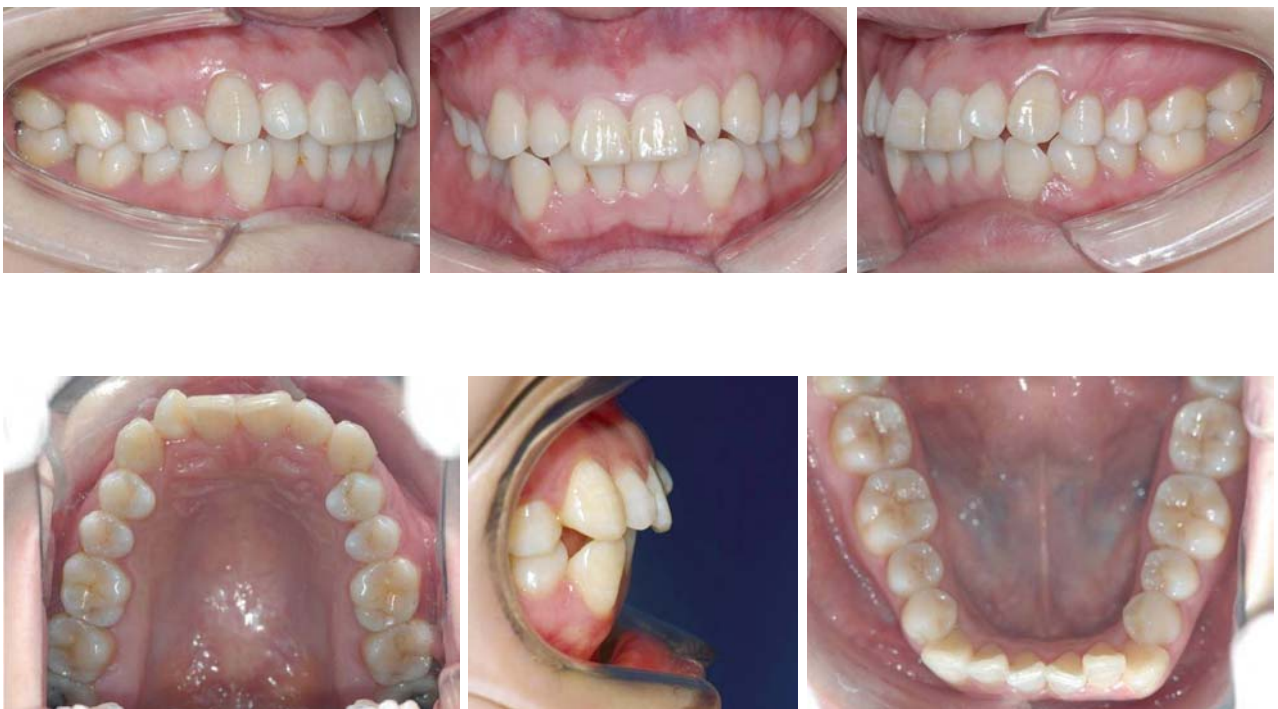Table 1: Cephalometric data

Measurement	Normal	Pretreatment	Post treatment
SNA	82±3	84	82
SNB	80±3	79	80
ANB	2±2	5	2
Interincisal(II)	131±6	115	128
SN-GO ME	32±4	33	30
MX1-SN	108±4	114	107
MX1-NA (angle)	22±3	30	24
MX1-NA(mm)	4±2	6	6
MAN1-NB(angle)	25±3	30	24
Man1-NB(mm)	4±2	6	3

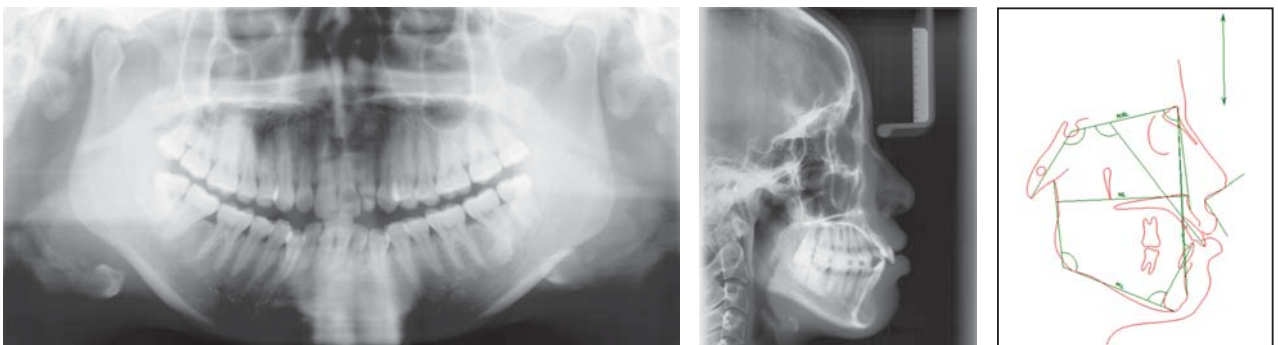
Case 2

A 36 years old female patient was referred to the orthodontic department by her prosthodontist. Her lower left second premolar and molars were missing due to which the upper second premolar and first molar had supra erupted (Fig 6). Due to this supra eruption, the restoration of lower edentulous area was not possible. The treatment plan was OMI assisted orthodontic intrusion of upper left second premolar and first molar so that lower edentulous area could be restored with dental implant. Two mini implants were inserted, one buccally and the other palatally. Second pre-molar was bonded while first molar was banded. The teeth were then intruded with elastic chain and Ni-Ti closed coiled spring (Fig 7). The total treatment duration was 6 months. The post-treatment photographs show well intruded teeth and lower edentulous area restored with dental implant (Fig 8).

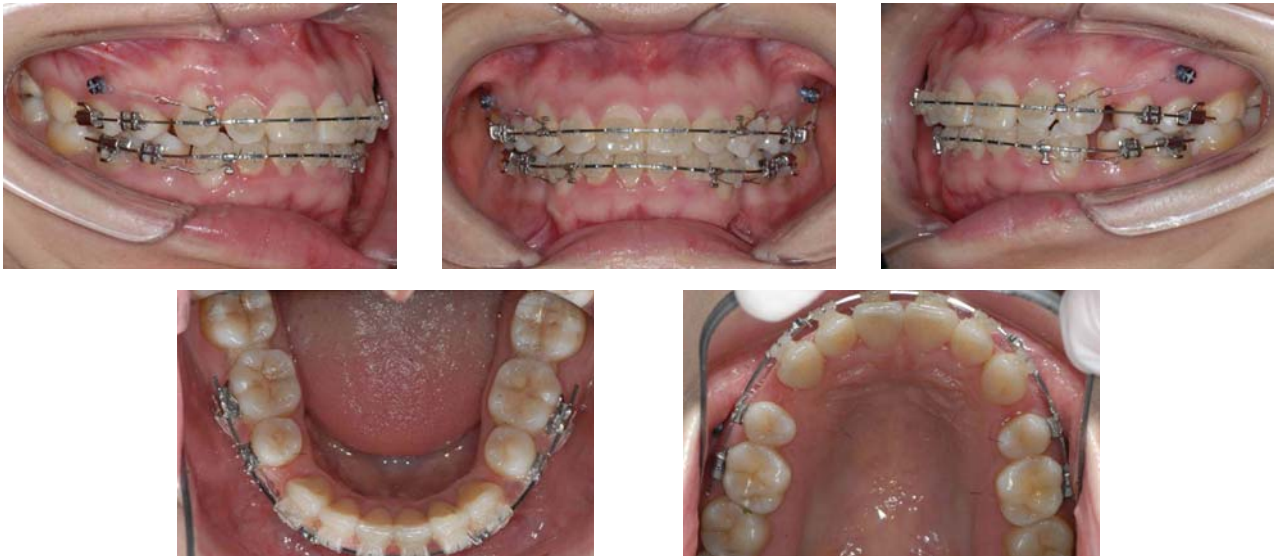
Case 1



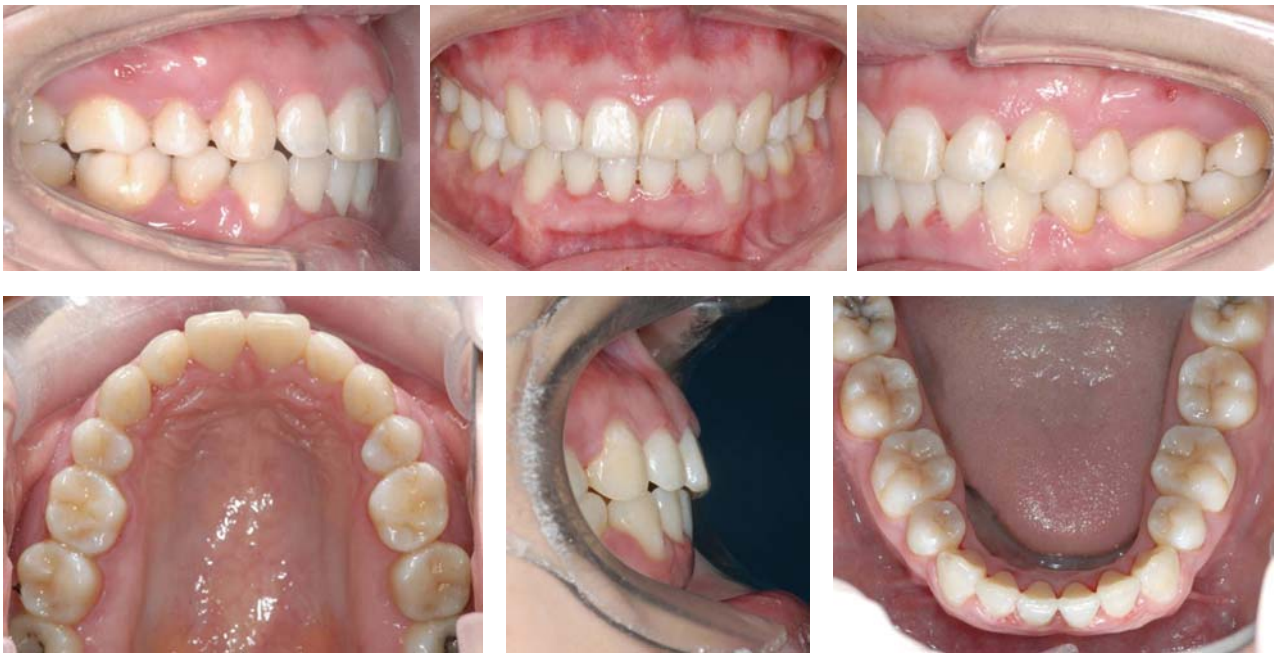Figs 1: (Case 1) Pre-treatment photographs showing crowding and protrusive profile



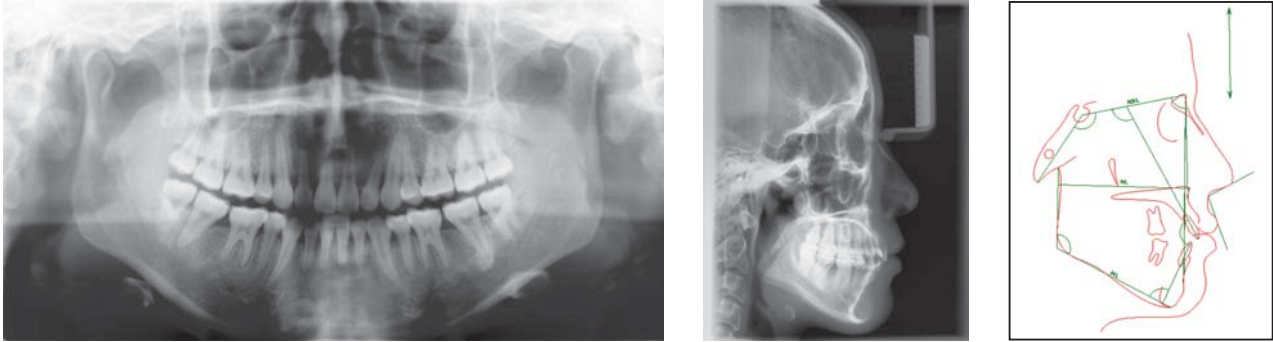
Figs 2: (Case 1) Pre-treatment OPG, Cephalogram and Cephalometric Tracing



Figs 3: (Case 1) During treatment, upper en-masse retraction with orthodontic mini implant

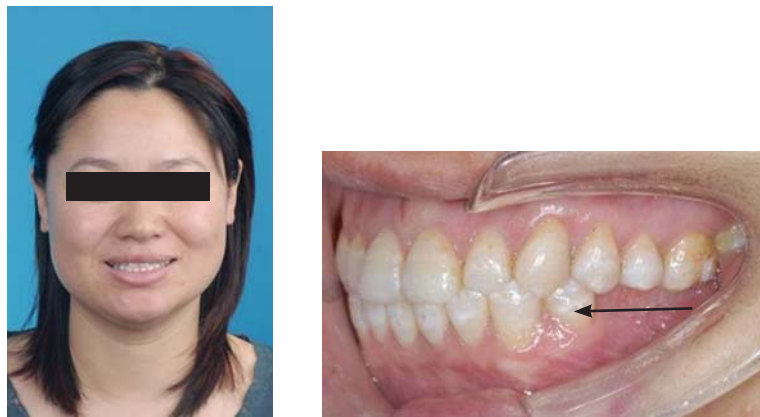

Figs 4: (Case 1) Post-treatment facial and intra-oral photographs

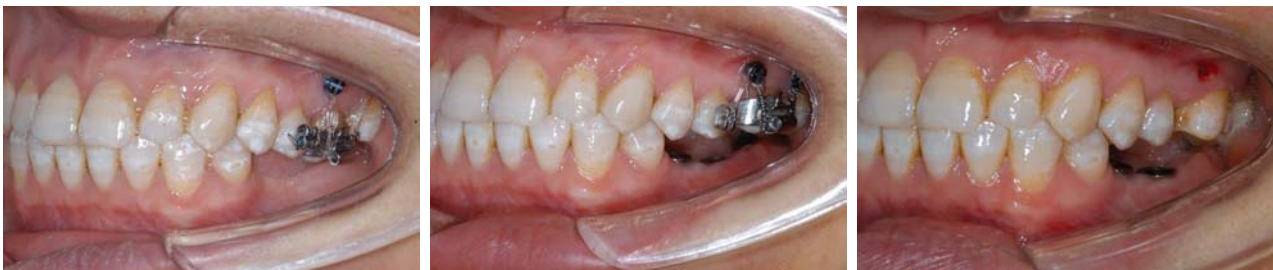

Figs 5: (Case 1) Post treatment OPG, Cephalogram and Cephalometric tracing

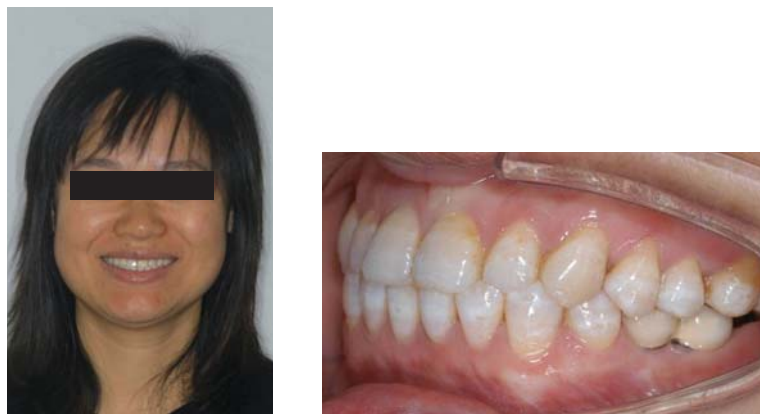Case 2



Figs 6: (Case 2) Pre-treatment facial and intra-oral photograph



Figs 7: Photographs at the start of treatment, during treatment and at the completion of treatment



Figs 8: Extra-oral and intra-oral photographs after occlusal restoration with dental implant

Discussion

In the first case, we decided to put two mini-implants in maxilla because of the need of maximum anchorage. Maximum anchorage can be obtained by the use of extra oral appliance e.g. headgear, TPA and OMI. But the patient compliance is the major factor. Especially the adult patients have poor compliance for the extra-oral appliances. TPA is commonly used to preserve the anchorage. But in cases of maximum anchorage needs, TPA is not the reliable option. To retract the teeth bodily, the line of applied force should pass through the centre of resistance^{15,16}. In our case the crimpable hook was not long enough to reach up to the centre of resistance of anterior teeth. This produced intrusive component in addition to retractive component which is beneficial in deep bite case. Orthodontic mini implant reduced the overall treatment time⁸.

Implant anchorage cannot increase the rate of tooth movement but it can definitely reduce the unwanted tooth movements. Nanda described the duration of orthodontic treatment still approaches 2 years: arguably because of the time it takes to correct the unintended side effects (undesirable tooth movements) that occur during tooth treatment¹⁷.

The mini-implant anchorage has predictable outcome which eliminates side effects. This may be the reason for decreased treatment time. Another reason for decreased treatment time is the anterior en-masse retraction. Canine does not need to be retracted individually which is usual procedure to preserve anchorage in conventional orthodontic treatment. Mini implant anchorage can be used to retract all the anterior teeth together.

In the second case of molar intrusion we placed two mini implants one on the palatal side and the other on the buccal side. Different ways of molar intrusion has been described in literature^{18,19}. To obtain the pure intrusion of molar and premolar the force should again pass through the centre of resistance, buccolingually as well as mesiodistally. Otherwise unwanted tipping of the tooth will result. If we can control the palatal force, then the tooth can be intruded with implant only on the buccal area. To obtain this mechanics, the heavy wire trans-palatal arch can be placed which prevents buccal tipping of the tooth. We can add palatal crown torque in TPA to add the intrusive effect of the buccal mini implant. If the line of force is applied through the centre of resistance, the molar intrusion can result in a short period of time. Usually the result can be seen within months of treatment. In our case, it took us six months to intrude the molar and sufficient space was available to put implant supported teeth in the lower jaw.

Conclusion

Mini-implant anchorage can produce highly predictable results with decreased treatment time and decreased side effects. Mini implant anchorage has expanded the horizon of orthodontic treatment towards orthognathic like effects remaining within the boundary of orthodontic domain.

References

1. Gainsforth BL, Higley LB. A study of orthodontic anchorage possibilities in basal bone. *Am J Orthod Oral Surg* 1945;31:406-17.
2. Branemark PI, Adell R, Breine U, Hansson BO, Lindstrom J, Ohlsson A. Intra-osseous anchorage of dental prosthesis. 1. Experimental studies. *Scand J Plast Reconstr Surg* 1969;3:81-100.
3. Linkow LI. Implant-orthodontics. *J Clin Orthod* 1970;4:685-90.
4. Creekmore TD, Eklund MK. The possibility of skeletal anchorage. *J Clin Orthod* 1983;17:266-9
5. Roberts WE: Endosseous miniscrews: Historical, vascular, and integration perspectives. In: Nanda R and Uribe FA, editors: *Temporary Anchorage Devices in Orthodontics* St. Louis: Mosby-Elsevier; 2009. p. 3-13.
6. Block MS, Hoffman DR. A new device for absolute anchorage for orthodontics. *Am J Orthod Dentofacial Orthop* 1995;107:251-8.
7. Kanomi R. Mini-implant for orthodontic anchorage. *J Clin Orthod* 1997;31:763-7.
8. Baumgaertel S, Razavi MR, Hans MG. Mini-implant anchorage for the orthodontic practitioner. *Am J Orthod Dentofacial Orthop* 2008;133:621-7.
9. Wilmes B, Rademacher C, Olthoff G, Drescher D. Parameters affecting primary stability of orthodontic mini-implants. *J Orofac Orthop* 2006; 67:162-74.
10. Park HS, Jeong SH, Kwon OW. Factors affecting the clinical success of screw implants used as orthodontic anchorage. *Am J Orthod Dentofacial Orthop* 2006; 130:18-25.
11. Cheng SJ, Tseng IY, Lee JJ, Kok SH. A prospective study of the risk factors associated with failure of mini-implants used for orthodontic anchorage. *Int J Oral Maxillofac Implants* 2004;19:100-6.
12. Kravitz ND, Kusnoto B. Risks and complications of orthodontic miniscrews. *Am J Orthod Dentofacial Orthop* 2007;131(4Suppl):43-51.
13. Kuroda S, Katayama A, Takano-Yamamoto T. Severe anterior open-bite case treated using titanium screw anchorage *Angle Orthod* 2004;74:558-67.
14. Liou EJW: Appliances, mechanics, and treatment strategies toward orthognathic-like treatment results. In Nanda R and Uribe FA Editors: *Temporary Anchorage Devices in Orthodontics*, St. Louis: Mosby-Elsevier; 2009. p. 167-97.

15. Burstone,C.J. and H.A.Koenig.Optimizing anterior and canine retraction. Am J Orthod 1976;70: 1-19.
16. Yoshida N, Jost-Brinkmann PG, Koga Y, Mimaki N, Kobayashi K. Experimental evaluation of initial tooth displacement, centre of resistance and centre of rotation under the influence of an orthodontic force. Am J Orthod Dentofacial Orthop 2001;120:190- 7.
17. Kulberg A, Nanda R. Principles of Biomechanics. In Ravindra Nanda editor: Biomechanics and Esthetic strategies in Clinical orthodontics, St. Louis; Elsevier-Saunders; 2005.p. 1-16.
18. Park HS, Jang BK, Kyung HM. Maxillary molar intrusion with micro-implant anchorage(MIA). Aust Orthod J 2005; 21:129-35.
19. Melson B, Fiorelli G. Upper Molar intrusion. J Clin Orthod 1996; 30:91-6.