

Non-surgical Management of Iatrogenic Furcal Perforation Using MTA: Case Report

Isha Lamichhane,¹ Sandhya Shrestha,² Richa Manandhar,³ Sadiksha Chaudhary⁴

¹⁻⁴Conservative Dentistry and Endodontics, Kantipur Dental College Teaching Hospital and Research Center,
Basundhara, Kathmandu, Nepal

Correspondence:

Isha Lamichhane. Email: isulamichhane41@gmail.com

ABSTRACT

One of the causes for perforation in furcal area is improper or misdirected use of burs during endodontic access cavity preparation or while locating root canal orifices. The prognosis of the perforation depends on its size, location and time of injury. Various materials have been proposed in the endodontic literature for managing such defects and MTA is widely used material. The purpose of this case report is to describe the management of two cases with furcal perforations. The perforations were sealed with MTA with internal matrix in one case and without in another case. At 1st, 3rd and 6th months there was the absence of pain, swelling with functional tooth stability and absence of periapical radiolucent lesion.

Keywords: Iatrogenic furcal perforation, MTA, Repair

INTRODUCTION

At present, root canal therapy is among the most frequently performed dental procedures, carried out not only by specialists but also by general practitioners. Nevertheless, with the growing number of endodontically treated teeth, likelihood of complications also rises.¹ One of the complications is root perforation at any levels. Root perforation is connection between the root canal system and surrounding periodontal tissues or oral cavity which is also caused during endodontic access cavity preparation or while locating root canal orifices due to improper or misdirected use of burs.² The frequency of iatrogenic root perforation in endodontically treated teeth ranges from 2% to 12%. Among all types of perforations, 47% occurred during root canal treatment, 73%

of maxillary and 23% of mandibular teeth were involved.³ The prognosis of perforation depends on size, location and time of injury.⁴ Regarding time, most favorable healing occurs when it is sealed immediately. Small perforations are associated with less tissue loss and periodontal inflammation, and healing is favorable. Perforations occurring in furcation region of multirouted teeth are regarded as particularly critical, since communication with epithelial attachment and gingival sulcus can trigger inflammatory responses, leading to periodontal tissue damage and potential tooth loss.

Citation

Lamichhane I et al. Non-surgical Management of Iatrogenic Furcal Perforation Using MTA: Case Report. *J Nepal Dent Assoc.* 2025 Jan-Jun;25(40):36-40.

This is an open access journal, and articles are distributed under the terms of the Creative Commons Attribution CC BY 4.0 Licence.

© 2025 JNDA | Published by Nepal Dental Association

The primary objective of perforation repair is to disinfect the affected site and seal using an appropriate restorative material. Various materials have been proposed in the endodontic literature for managing such defects. However, among these, calcium silicate–based cement, particularly Mineral Trioxide Aggregate (MTA) has been most widely employed for furcal perforation repair because of its superior osteogenic and regenerative properties.⁵ It is a biocompatible material that does not cause excessive inflammation and promotes a favorable environment for cells. It can set and harden in presence of blood and tissue fluids, which is a common situation in the furcal perforation.⁶

The purpose of this case report is to highlight the management of iatrogenic perforations at furcation level.

CASE 1:

A 58 year-old female was referred to the Department of Conservative Dentistry and Endodontics, Kantipur Dental Hospital. The previous dentist referred for the iatrogenic error during access opening where the dentist was unable to locate the root canal orifice and noted perforation in the furcation area and patient came to our department after 1 day.

On examination, temporary restorative material was present in tooth 46 with no sensitivity to percussion and palpation test. The mean probing depth was within normal level. The radiographic examination showed a radiolucent area in furcal area (Figure.1). The temporary restorative material was removed, and large perforation of approximately 3x4mm was encountered. Hemorrhage was controlled with sodium hypochlorite. Three canals (Mesio Buccal, Mesio lingual and distal) were located, negotiated and coronal third enlarged with Protaper SX (Superendo) (Figure.2). Canal was irrigated with 2% CHX and teflon tape was placed in canal orifice to temporarily seal the canal. (Figure.3). Perforation site was disinfected with 3% sodium hypochlorite. Gel foam was placed in perforation area to form a barrier between periodontal area and repair material. Mineral Trioxide aggregate (Angelus, Brazil) was mixed as per manufacturer instructions in 3:1 proportion and was compacted in the perforation area to seal it under dental operating microscope. Moist cotton pellet was placed in the pulp chamber to produce a humid environment for MTA to achieve its solidification and temporary restorative material was placed. The patient returned to the department after 48hrs with no signs and symptoms. Temporary sealing materials and the wet cotton pellet were removed, and the hardness of the MTA was gently

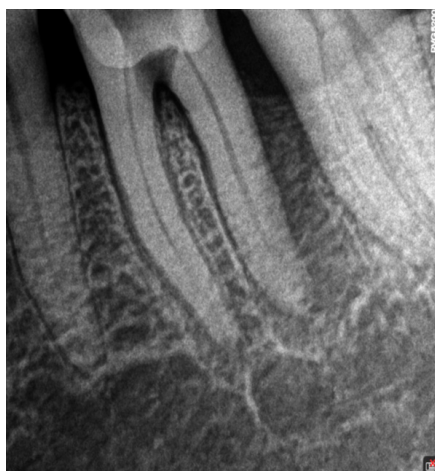


Figure 1: Preoperative Radiograph showing radiolucency in furcal area indicating perforation

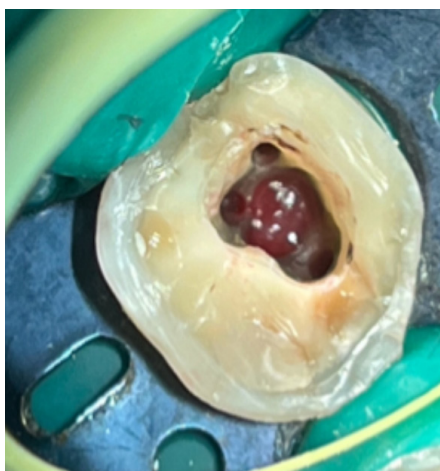


Figure 2: Clinical picture of perforation after locating and coronal flaring all three canals

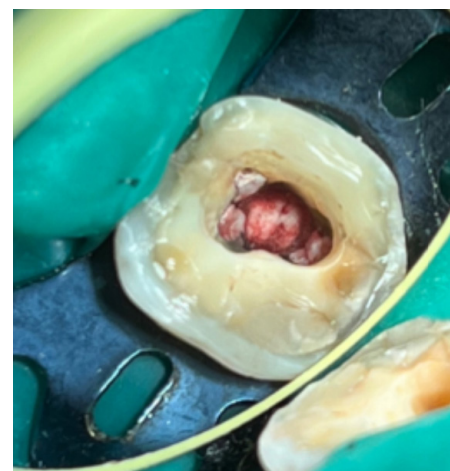

Figure 3: Placement of Gel foam as an internal matrix and Teflon tape in orifice

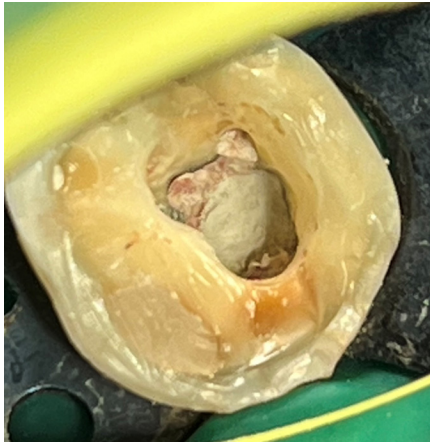

Figure 4: After perforation seal

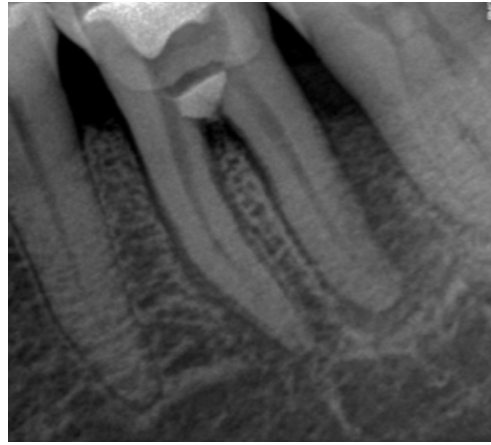


Figure 5: Perforation repair with MTA

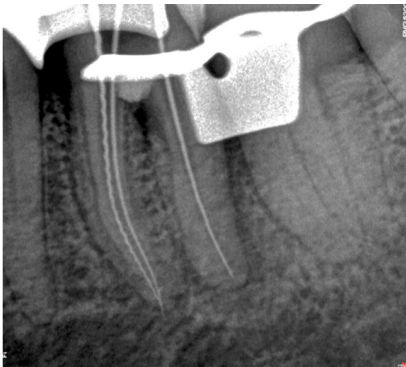


Figure 6: Working length determination

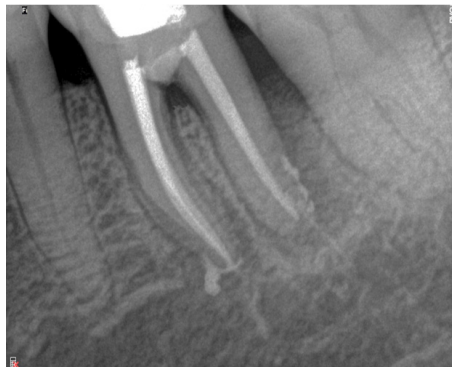

Figure 7: Obturation

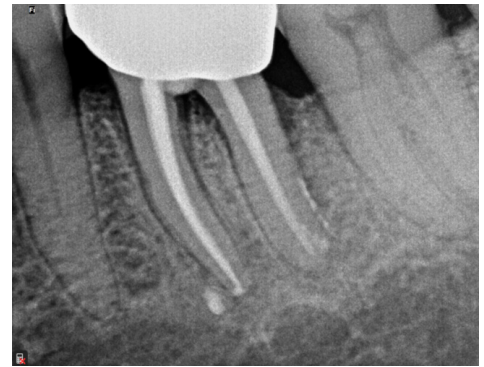


Figure 8: 6 months follow up

tested with an operative explorer. Working length was determined, confirmed with apex locator and biomechanical preparation was done with Protaper (Superendo), till F2 for mesial canals and till F3 for distal canal with copious irrigation with 3% Sodium hypochlorite and ultrasonic activation. Calcium hydroxide intracanal medicament was placed, and patient was recalled after 1 week then obturation was done after using final irrigation protocol (3% sodium hypochlorite, Normal saline, 17% EDTA, 2% CHX) and using single cone technique with GP and bioceramic sealer. (Figure. 4).

At the 6-month follow-up, the tooth remained asymptomatic. The clinical examination showed no pain, no response to percussion and palpation. There were normal probing depths. Radiographic examination shows bone formation in distal surface of distal root and in the furcal area

Case 2

A 40 year-old female was referred to the Department of Conservative Dentistry and Endodontics, Kantipur Dental Hospital for iatrogenic error that occurred during access opening while locating canals. The patient complained of spontaneous pain in lower left back tooth region. The patient said that root canal treatment was started, and she was referred to our department after 1 week of initial appointment.

On clinical examination, temporary filling was present in tooth 36. The tooth 36 had pain on percussion but no tenderness on palpation, no mobility and probing depth was within normal limit. Temporary filling was removed, small perforation of approximately 2 mm was detected in furcal area, file was placed and RVG was taken

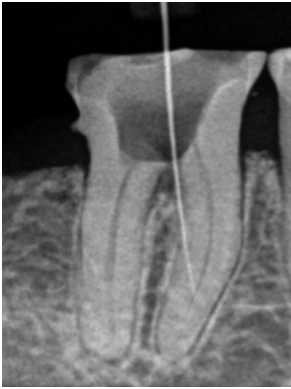

Figure 9: Preoperative Radiograph

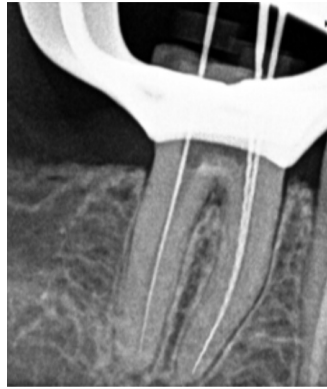

Figure 10: Working length determination

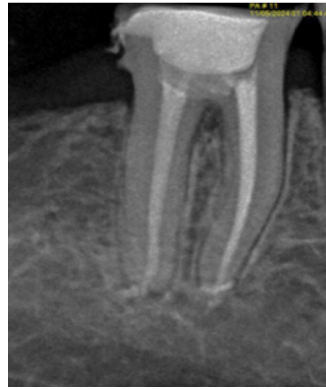

Figure 11: Obturation

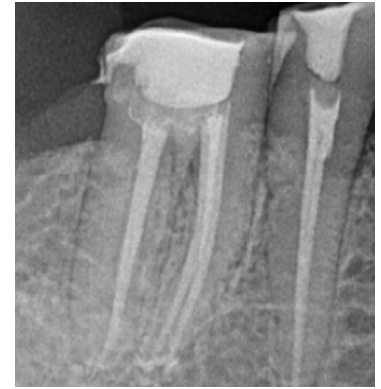

Figure 12: 3- months follow-up

to confirm it. (Figure 8) Three canals were located (Mesiobuccal, Mesiolingual and Distal canal). Canals were negotiated and coronal 3rd enlarged with Protaper SX (Superendo) with copious irrigation by 3% sodium hypochlorite. Teflon tape was placed to temporarily seal the canal, but the internal matrix was not placed as the perforation was small. Perforation site was disinfected with 3% sodium hypochlorite. MTA was mixed as manufacturer instruction and placed in perforation site, moist cotton pellet and temporary filling was placed. Patient was recalled after 48hrs, GIC was placed in floor above MTA. Working length was determined, canals were prepared till Protaper F2 for mesial roots and till F3 for distal roots and intracanal medicament was placed. On the next visit obturation was done as in case 1.

At 3 months follow up patient was asymptomatic, no pain, no response to percussion, palpation and normal probing depths and radiographic examination shows no significant finding.

DISCUSSION

Root perforations may result from pathological causes such as resorption or caries, or they may be iatrogenic, occurring accidentally during root canal procedures. Studies report that approximately 2%–12% of endodontically treated teeth experience accidental perforations.³

The prognosis of a perforation is influenced by factors such as its location, size, and the duration of contamination. Furcal perforations situated near the epithelial attachment and crestal bone are generally associated with a guarded prognosis. Additionally, the size of the perforation plays a crucial role in the success of the repair. Several authors recommend using an internal matrix to prevent extrusion of the repair material and subsequent inflammation of the periradicular tissues.⁷ In these cases, the first one had larger perforation so the gel foam was placed as an internal matrix to prevent the extrusion of repair materials but the perforation was small in second case so internal matrix was not placed. The time interval between the occurrence of a perforation and its repair is a key determinant of treatment success. Immediate sealing of the perforation promotes better healing by minimizing the risk of bacterial contamination at the defect site. In the present case report, first case was sealed after 2 days whereas in second case it was sealed after 1 week.

The factor that is within the control of operator is the choice of material used for furcation repair. In previous years, materials such as amalgam, composite resin, and glass ionomer cement were commonly used to seal furcal perforations. However, research indicates that MTA demonstrates superior performance compared to these materials in terms of marginal adaptation, resistance to bacterial leakage, cell adhesion ability to regenerate and lower

cytotoxicity.⁸ Nazir et. al.⁹ concluded that MTA offers a reliable seal for root perforations and can serve as an effective repair material, improving the prognosis of teeth that might otherwise have a poor outcome. In the present cases, a furcal perforation that occurred during endodontic treatment was successfully repaired non-surgically using Mineral Trioxide Aggregate (MTA). The tooth remained asymptomatic with normal probing depth and radiographic evidence of periradicular healing at follow-up, indicating favorable clinical and biological response. There was not any difference in healing time between two cases and long-term follow-up is required to consider it as success.

As the prevention is always better, iatrogenic errors can be prevented through proper preoperative assessment, considering factors like the position of the tooth roots, the crown-root relationship, the

tooth's rotation within the arch, and the alignment of the incisal edge or cusp tip with the root's long axis. Also, the use of magnification plays an important role to minimize the iatrogenic errors.

SUMMARY

These cases reinforces that with proper diagnosis, magnification, and use of advanced biomaterials like MTA, non-surgical management of iatrogenic furcal perforations can yield predictable responses. Emphasis should always be placed on prevention through proper preoperative assessment and careful operative technique.

Conflict of interest: None



REFERENCES

1. Pietrzycka K. Furcal area and root canal perforations treatment – case series report and literature review. *Pomeranian J Life Sci.* 2024;70(2). [[DOI](#) | [Google scholar](#) | [Full Text](#)]
2. Aidasani G, Mulay S. Management of iatrogenic errors: Furcal perforation. *J Int Clin Dent Res Organ.* 2018;10(1):42. [[Google scholar](#) | [Full Text](#)]
3. Alshehri MM, Alhawsawi BF, Alghamdi A, Aldobaikhi SO, Alanazi MH, Alahmad FA. The management of root perforation: A review of the literature. *Cureus.* 2024;16(10):e72296. [[DOI](#) | [PubMed](#) | [Full Text](#)]
4. Drs J, Drs G, Dra K. Management of Furcal and Subcrestal Perforation with a Bioactive Material - A Case Report. *Int J Res Rev.* 2022;9(5):267–71. [[Full Text](#)]
5. Dutta S, Gupta S, Yadav M. Management of furcation perforation using Mineral trioxide aggregate in Young permanent molar- A 12 months follow up. *Int J Oral Health Dent.* 2022;8(4):329–32. [[DOI](#) | [Full Text](#)]
6. Ali S, Zoya A, Fatima A. Management of iatrogenic root perforation with grade II furcation involvement through guided tissue regeneration technique: A case with comprehensive review of clinical literature. *Saudi Endod J.* 2022;12(1):129. [[DOI](#) | [Google Scholar](#) | [Full Text](#)]
7. Unal GC, Maden M, Isidan T. Repair of furcal iatrogenic perforation with mineral trioxide aggregate: Two years follow-up of two cases. *Eur J Dent.* 2010;04(04):475–81. [[DOI](#) | [PubMed](#) | [Full Text](#)]
8. Pinheiro LS, Kopper PMP, Quintana RM, Scarparo RK, Grecca FS. Does MTA provide a more favourable histological response than other materials in the repair of furcal perforations? A systematic review. *Int Endod J.* 2021;54(12):2195–218. [[DOI](#) | [PubMed](#) | [Full Text](#)]
9. Nazeer A, Nazir A, Manzoor SA, Khan MA, Shaukat Z, Saleem M, et al. Efficacy of mineral trioxide aggregate (MTA) as a reparative material in iatrogenic furcal perforations in mandibular molars. *Cureus.* 2024;16(1): e53206. [[DOI](#) | [PubMed](#) | [Full Text](#)]