

Assessment of the Distance Between the Osteotomy Line and the Inferior Alveolar Nerve for harvesting Ramus Bone Graft: A Cone Beam Computed Tomography (CBCT) analysis

Siddhartha Rai,¹ Mehul Rajesh Jaisani,² Santosh Kumari Agrawal,³ Abhinaya Luitel,⁴

Bibek Kattel,⁵ Niroj Khanal,⁶ Akanksha Badhu,⁷ Prajwal Gajurel⁸

^{1,2}Department of Oral and Maxillofacial Surgery, BP Koirala Institute of Health Sciences, Dharan, Koshi, Nepal

³Department of Public Health Dentistry, BP Koirala Institute of Health Sciences, Dharan, Koshi, Nepal

⁴Department of Oral medicine and Radiology, BP Koirala Institute of Health Sciences, Dharan, Koshi, Nepal

⁵BDS, College of Dental Surgery, BP Koirala Institute of Health Sciences, Dharan, Koshi, Nepal

⁶Department of Oral and Maxillofacial Surgery, Rapti Academy of Health Sciences, Dang, Nepal

⁷Department of Oral Pathology, People's Dental College, Kathmandu, Nepal

⁸School of Public Health and Community Medicine, BP Koirala Institute of Health Sciences, Dharan, Koshi, Nepal

Correspondence :

Bibek Kattel. Email: enigmatic.cyper97@gmail.com

ABSTRACT

Background: Harvesting ramus block grafts carries a potential risk of inferior alveolar nerve (IAN) exposure or injury, particularly when the osteotomy line is positioned close to the mandibular canal. Accurate evaluation of this anatomical relationship is essential to minimize neurosensory complications. This study aimed to evaluate the osteotomy line–IAN distance using cone beam computed tomography (CBCT) to assess the potential risk of nerve exposure.

Methods: A retrospective analysis was conducted on CBCT scans of 28 patients (56 mandibular halves), aged 18–60 years. Using Rainbow 3D Viewer 1.1.0 (Dentium) and following the Misch and Khoury technique, the ramus graft outline was traced. Key parameters measured included graft length, the distance between the osteotomy line and the IAN canal (IANC), total thickness of the graft and cortical bone.

Results: The mean distance between the osteotomy line and the IANC was 3.27 ± 1.14 mm. The mean maximum graft thickness and cortical thickness were 3.89 ± 0.46 mm and 3.67 ± 0.64 mm, respectively. In three cases, direct contact between the osteotomy line and the IAN was observed.

Conclusions: Temporary neurosensory disturbances remain a potential risk when the osteotomy line approximates the IAN, despite the rarity of permanent nerve damage. CBCT is a valuable tool for evaluating anatomical relationships prior to graft harvesting.

Keywords: Autograft, inferior alveolar nerve; cone-beam computed tomography; paresthesia.

INTRODUCTION

Endosteal dental implants require adequate alveolar bone quantity and quality to ensure an aesthetic and functional outcome of the final prosthesis.¹ When the alveolar site receiving the implants lacks the required bone volume, then bone

Citation

Rai S et al. Assessment of the Distance Between the Osteotomy Line and the Inferior Alveolar Nerve for harvesting Ramus Bone Graft: A Cone Beam Computed Tomography (CBCT) analysis. *J Nepal Dent Assoc.* 2025 Jan-Jun;25(40):3-10 .

This is an open access journal, and articles are distributed under the terms of the Creative Commons Attribution CC BY 4.0 Licence.

© 2025 JNDA | Published by Nepal Dental Association

augmentation becomes a necessity. The available options for alveolar bone augmentation range from autografts, allografts, xenografts, alloplasts, and even composite grafts.^{2,3} Autografts possess osteogenic, osteoinductive, and osteoconductive properties and have shown a lower risk of graft failure and improved success rates. Additionally, due to the intramembranous embryonic origin, bone grafts from intraoral sites resorb less compared to endochondral bone grafts taken from the iliac crest, rib, and tibia.^{4,5}

Harvesting autografts from intraoral sites offers several advantages, including reduced anaesthesia requirements, minimal blood loss, and the absence of visible scars associated with extraoral graft harvesting. Additionally, because the defect areas requiring endosteal dental implants are often smaller, the amount of bone harvested from intraoral sites is generally sufficient for augmentation. As a result, intraoral autografts for dental implant reconstruction remain a preferred choice.⁶

Block grafts are commonly harvested from the mandibular symphysis or ramus. Ramus graft harvesting is associated with fewer postoperative complications compared with symphysis grafts. In contrast, symphysis graft harvesting carries a higher risk of neurosensory disturbances involving the lower lip, chin, and mandibular anterior teeth. Temporary sensory disturbances are reported in approximately 9.6% to 46.6% of patients and permanent neurosensory deficits in up to 13.5%.⁷ Additionally, concerns exist regarding donor site augmentation. The use of a sulcular incision may increase the risk of gingival recession, and improper closure of the sublabial incision can lead to chin ptosis.^{8,9}

While the graft length obtained from the ramus is typically greater than that from the symphysis, its thickness tends to be smaller. However, when bilateral ramus grafts are harvested, the total volume of bone harvested is generally greater.¹⁰ The classic techniques developed by Misch¹¹ and Khoury¹² for harvesting ramus block grafts highlight the

potential risk of inferior alveolar nerve (IAN) injury during the procedure. The risk of nerve injury increases when larger grafts are needed, as the inferior aspect of the graft may extend up to or below the position of the IAN. The proximity of the osteotomy line to the IAN canal (IANC) in such cases could be a key factor in determining the risk of nerve injury.¹² Ramus block grafts are predominantly composed of cortical bone, with little or no marrow. Consequently, the overall graft thickness tends to correspond primarily to the cortical thickness, which varies in a non-uniform manner across different cross-sections.^{12,13}

This variability in graft thickness and the proximity of the osteotomy line to the IAN canal underscore the importance of preoperatively assessing the risk of nerve injury during ramus graft harvesting. By predicting the likelihood of intraoperative nerve exposure, this study aims to utilize cone beam computed tomography (CBCT) to outline the ramus graft and measure the distance between the osteotomy line and the IAN. This study aims to evaluate the potential risk of nerve injury, allowing clinicians to anticipate and mitigate the risk of nerve exposure/injury during the harvesting procedure.

METHODS

This study was approved by the Institutional Review Committee of B.P. Koirala Institute of Health Sciences (BPKIHS), Dharan (Ref. No. 187-081-82). CBCT records of patients who underwent radiographic investigations between February and July 2024 were included using convenience sampling. Based on an alpha error of 5% and a study power of 80%, and with reference to the study by Leong et al.¹³, the estimated sample size was 28 CBCT scans (56 hemi-mandibles).

The inclusion criteria comprised patients with bilateral impacted mandibular third molars who had undergone CBCT imaging as part of the preoperative assessment to evaluate the risk of inferior alveolar nerve (IAN) injury. This patient group was selected because their CBCT scans were readily available in

the institutional database. Hence, the study utilized existing diagnostic scans from this group to evaluate anatomical parameters relevant to ramus bone graft harvesting. Patients with a history of fractures involving the body or angle of the mandible, or those who were edentulous, were excluded from the study.

CBCT Image Analysis

The Digital Imaging and Communications in Medicine (DICOM) files of the CBCT scans were analysed using Rainbow 3D Viewer 1.1.0 (Dentium). The total length of the ramus graft was determined by tracing a line from the distal surface of the first molar crown along the occlusal surface of the second molar, parallel to the first and second molars, until it contacted the anterior border of the ramus of the mandible (Figure 1). This total graft length was then divided into three approximately equal segments (mesial, middle, and distal thirds), and measurements were obtained at the midpoint of each segment. The final values were calculated as the average of measurements from these three points.

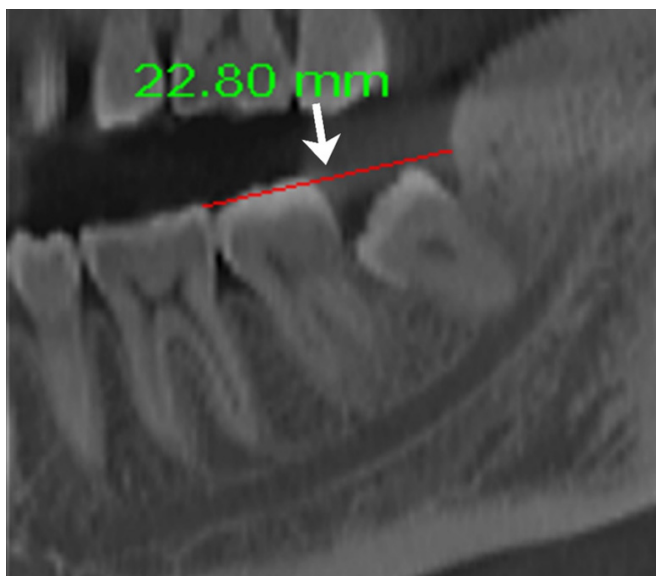


Figure 1: The red line represents the total length of the graft extending from the distal aspect of the first molar to the anterior border of the ramus.

Distance Between the IAN Canal (IANC) and Osteotomy Line (OL)

Following the Misch¹¹ and Khoury¹² technique, a line was drawn parallel to the buccal cortex from a point 5 mm medial to the external oblique ridge, extending to the level of the most prominent part of the IANC. This line represented the osteotomy line (OL). The distance between the IAN and OL was measured at the three previously defined regions (mesial, middle, and distal thirds) to evaluate IAN approximation (Figure 2).

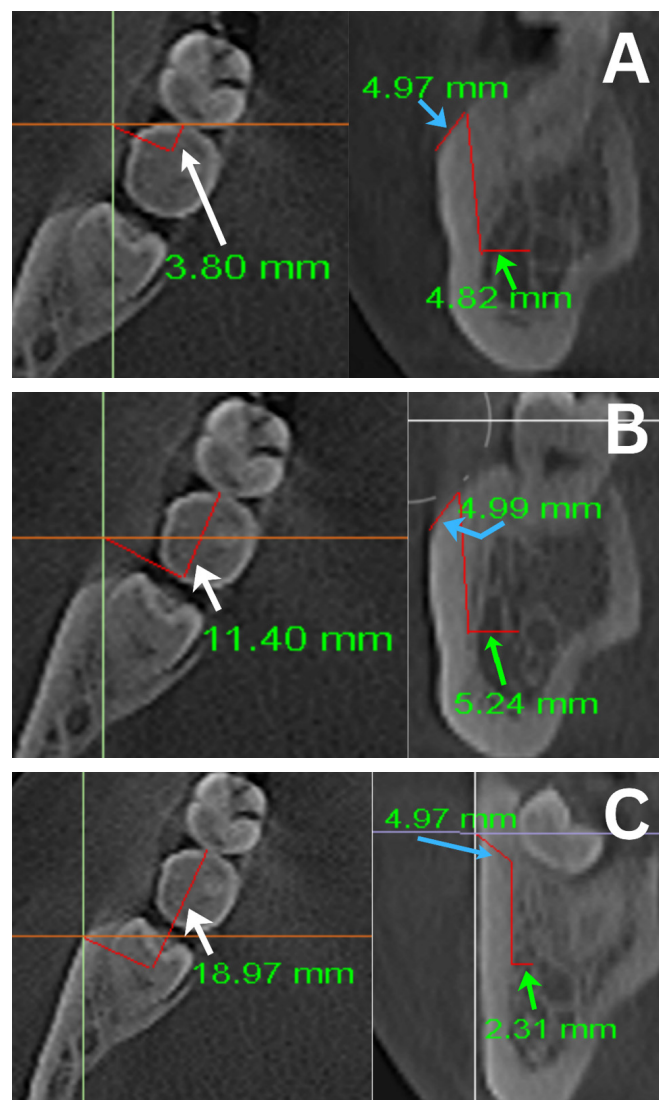


Figure 2: Axial sections demonstrating measurements obtained at the midpoints of the mesial, middle, and distal thirds of the total graft length (white arrow), with corresponding coronal sections showing the distance between the inferior alveolar nerve (IAN) and the osteotomy line (OL) (arrowheads). A) Mesial third, B) Middle third, C) Distal third.

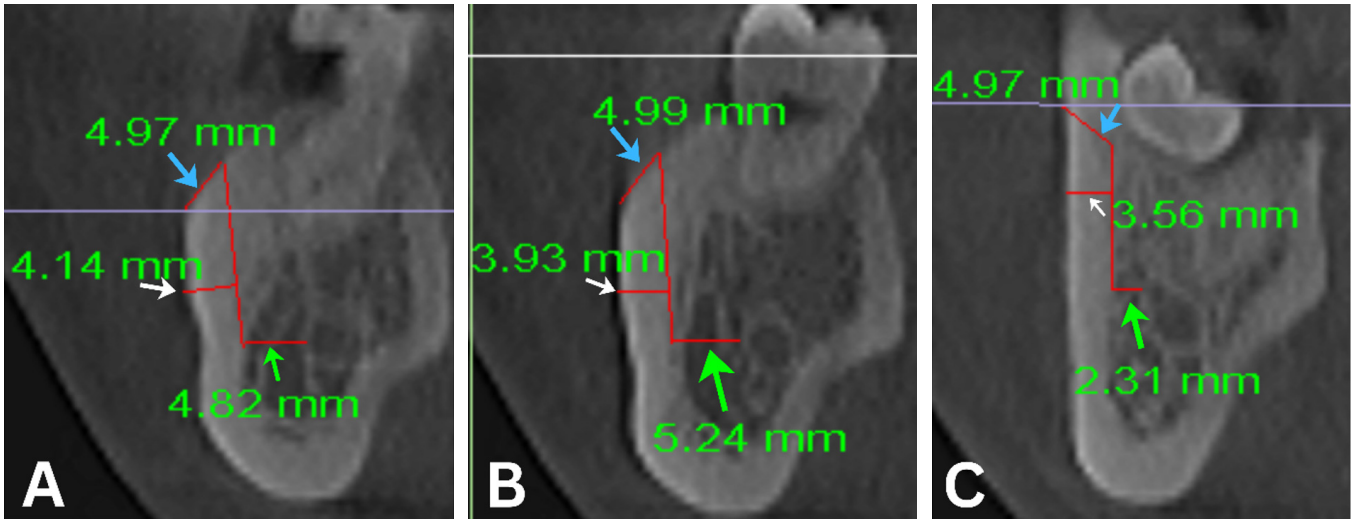


Figure 3: Thickness of the graft measured in coronal sections. The white arrow indicates the graft thickness, demonstrating completely cortical bone in this region. The blue arrow denotes the approximate 5 mm distance measured from the external oblique ridge along the cortical surface, while the green arrow represents the distance between the osteotomy line and the inferior alveolar nerve. Measurements are shown for the A) Mesial third, B) Middle third, and C) Distal third.

Maximal thickness of the graft and cortex

The maximum distance between the buccal cortex and the OL was measured at the three sites mentioned above. The average of these three measurements was taken as the final mean thickness of the graft. For the cortical thickness, the marrow portion was subtracted from the total graft thickness (Figure 3).

Statistical analysis

The statistical analyses of the data used in the study were performed via the statistical package for the social science (SPSS, Chicago, IL, USA), version 26. Descriptive statistics were presented as frequency, percentages, mean, and standard deviations. ANOVA and an Independent t-test were used to compare the means of the variable after checking for data normality. Intraclass correlation coefficient was calculated for intra-examiner reliability of measurement, IAN, and OL was found to be 0.75, indicating almost perfect agreement. Statistical significance was considered at a level of $p < 0.05$.

RESULTS

A total of 56 hemi-mandibles from 28 CBCT scans were included in the study, comprising 15 females and 13 males. Measurements for each hemi-mandible were averaged at the midpoint of the mesial, middle, and distal thirds.

The mean distance between the osteotomy line (OL) and the inferior alveolar nerve (IAN) was shortest in the distal third and greatest in the mesial third on both sides. This regional variation was statistically significant on the right side ($p = 0.001$), while a similar trend on the left side did not reach statistical significance ($p = 0.12$). No statistically significant difference was observed between the right and left sides for the overall OL–IAN distance ($p = 0.205$). Regarding graft dimensions, the maximum graft thickness (combined cortical and marrow components) was greatest in the middle third on both sides, with statistically significant regional differences on both the right ($p = 0.001$) and left sides ($p = 0.002$). Inter-side comparison demonstrated a significantly greater graft thickness on the left side

compared with the right ($p = 0.015$). The cortical thickness followed a similar distribution pattern, being greatest in the middle third bilaterally, with significant regional and inter-side differences ($p = 0.001$) (Table 1).

No statistically significant differences in any measured parameters were observed between males and females (Table 2).

The mean total graft length was 25.57 ± 2.46 mm, and the overall mean distance between the OL and the IAN was 3.27 ± 1.14 mm. The mean maximum graft height, overall graft thickness (cortex + marrow), and cortical thickness were 15.24 ± 2.01 mm, 3.89 ± 0.46 mm, and 3.67 ± 0.64 mm, respectively (Table 3). In three patients, the osteotomy line was found to be in direct contact with the inferior alveolar nerve.

Table 1: (Mean \pm standard deviation) of IAN approximation, length, height, maximum thickness of the graft and cortex in each mandibular half (58 hemi- mandibles)

Parameters (mm)	Hemi-mandible	Mesial 1/3 rd	Middle 1/3 rd	Distal 1/3 rd	p-value*	p-value** between left and right
Distance between IAN and OL	Right	3.58 ± 1.34	3.45 ± 1.38	2.32 ± 1.26	0.001	0.205
	Left	3.66 ± 1.62	3.69 ± 1.58	2.90 ± 1.63	0.12	
Maximum thickness of the graft	Right	3.81 ± 0.75	4.36 ± 0.60	3.49 ± 0.65	0.001	0.015
	Left	4.14 ± 0.90	4.55 ± 0.61	3.84 ± 0.58	0.002	
Maximum thickness of the cortex	Right	3.66 ± 0.51	4.09 ± 0.47	3.11 ± 0.61	0.001	0.001
	Left	3.80 ± 0.75	4.11 ± 0.48	3.25 ± 0.54	0.001	

* ANOVA

** INDEPENDENT T TEST

IAN= Inferior Alveolar Nerve, OL- Osteotomy Line. ANOVA- Analysis of Variance

Table 2: Comparison of the IAN approximation, length, height, maximum thickness of the graft and cortex among males and females (58 hemi- mandibles)

Parameters (mm)	Gender	Mean \pm S.D	p-value*
Distance between IAN and OL	Male	3.29 ± 1.16	0.656
	Female	2.97 ± 1.04	
Maximum thickness of the graft	Male	3.91 ± 0.42	0.886
	Female	3.87 ± 0.51	
Maximum thickness of the cortex	Male	3.66 ± 0.38	0.862
	Female	3.59 ± 0.33	
Length of the graft	Male	25.75 ± 2.28	0.260
	Female	25.34 ± 3.18	

* independent sample t-test

p-value < 0.05 is statistically significant

IAN= Inferior alveolar Nerve, OL- Osteotomy Line, S.D - Standard Deviation

Table 3: Total average measurement of IAN approximation, length, height, maximum thickness of the graft and cortex of the ramus graft (58 hemi- mandibles)

Parameters	Mean \pm standard deviation
Length of the graft (mm)	25.57 \pm 2.46
Distance between IAN and OL (mm)	3.27 \pm 1.14
Maximum thickness of the graft (mm)	3.89 \pm 0.46
Maximum thickness of the cortex (mm)	3.67 \pm 0.64

IAN= Inferior alveolar Nerve, OL- Osteotomy Line

DISCUSSION

Grafts harvested from the external oblique ridge require meticulous preoperative planning, particularly for implant placement, where three-dimensional assessment with CBCT is essential. Since CBCT is a standard practice for implant planning, the same level of assessment is necessary for evaluating intraoral donor sites to ensure anatomical safety and minimize surgical risks. While studies have shown that neurosensory disturbances are less frequent with external oblique ridge grafts compared to symphysis grafts, CBCT can provide an additional layer of assurance by helping to assess the likelihood of nerve exposure preoperatively.

Leong et al.¹³ observed IAN exposure in all cadaveric mandibles in their study but noted that continuity of the nerve was maintained, suggesting no direct nerve injury. However, other studies, including those by Khoury et al.¹² and Bayram et al.¹⁴, reported significant post-operative temporary paresthesia in cases where the IAN was exposed, with symptoms lasting from a few weeks to up to a year. Although permanent paresthesia has not been reported, temporary sensory disturbances require careful consideration, as they may necessitate pharmacological management.¹⁵ By outlining the approximate graft size and measuring its relationship with the IAN, this study highlights the potential of CBCT in preoperatively predicting IAN exposure, thereby aiding in risk assessment and surgical planning.

In this study, the average distance between the osteotomy line and IAN was 3.27 \pm 1.14 mm, with

the greatest distance observed in the mesial third and the shortest in the distal third. This aligns with findings from Misch¹¹ and suggests that if a thicker graft is required, the anterior osteotomy can be positioned distal to the first molar. However, among the three cases where the osteotomy line directly contacted the buccal aspect of the IAN, one measurement fell within the middle third, indicating that individual anatomical variations may predispose some patients to a higher risk of nerve exposure. This highlights the importance of pre-surgical virtual mock outlines of the proposed graft, which can help in patient counselling regarding the potential risks of IAN exposure and paresthesia. Additionally, such preoperative assessments allow the surgeon to modify the osteotomy design to reduce the risk of nerve injury.

Although literature reports that ramus grafts can extend up to 35 mm, harvesting from the ascending ramus requires extensive flap elevation and osteotomy extension, which can be surgically challenging.¹⁶ In contemporary implant dentistry, the most practical graft harvesting sites are the buccal shelf or external oblique ridge.^{12,17,18} The mean graft length in this study was 25.57 \pm 2.46 mm, which is sufficient for augmenting alveolar defects spanning two missing teeth. Additionally, the mean graft thickness was 3.89 \pm 0.46 mm, consistent with previous reports by Misch¹¹ and Sittitavornwong.¹⁹ The greatest graft thickness was measured in the middle third, just distal to the second molar, while the distal third (ascending ramus region) had the least thickness. This finding aligns with the study by Leong et al.,¹³ which reported a maximum cortical thickness of 2.3 \pm 0.7

mm in the second molar region. However, our study observed a higher cortical thickness (3.67 ± 0.64 mm) in the region just distal to the second molar, suggesting that this site may offer a more robust cortical bone graft source. The external oblique ridge graft consists predominantly of cortical bone with minimal marrow content.⁹ By subtracting cortical thickness from the total graft thickness, the marrow space was estimated to be approximately 0.22 mm only.

This study has several limitations. First, CBCT scans were obtained from patients with impacted mandibular third molars, which may not fully represent the anatomical characteristics of patients without third molars. However, due to ethical constraints, obtaining CBCT scans purely for anatomical research without clinical necessity is not permissible. Thus, the study leveraged existing diagnostic imaging to minimize patient exposure while enabling relevant anatomical analysis. Second, the retrospective design and single-institution setting may introduce selection bias and restrict external validity. Third, although standardized tracing based on established techniques was used, the measurement methodology was not validated against intraoperative findings or alternative imaging modalities, which may affect measurement accuracy. Notably, the osteotomy line was closest to the IAN in the distal third, which corresponds to the region of impacted third molars. Patients with congenital third molar agenesis or early third molar removal may exhibit variations in IAN positioning.²⁰

Future directions:

Future studies should include larger and more diverse populations, including patients without impacted third molars, to better account for anatomical variability. Prospective clinical studies correlating CBCT-based measurements with intraoperative nerve exposure and postoperative neurosensory outcomes would further strengthen the clinical applicability of these findings. Additionally, the integration of advanced digital

tools, including artificial intelligence–assisted segmentation and measurement techniques, may improve accuracy, reproducibility, and efficiency in three-dimensional anatomical assessment, thereby supporting clinicians in optimizing surgical strategies for ramus graft harvesting.

CONCLUSIONS

Cone beam computed tomography (CBCT) is essential for preoperative assessment of inferior alveolar nerve (IAN) proximity during ramus bone graft harvesting. The distal third of the ramus represents the region at highest risk for nerve approximation, emphasising the need for careful osteotomy planning in this area. Given the observed anatomical variability and the potential for transient neurosensory disturbances, individualised CBCT-based surgical planning is crucial to minimise nerve exposure and optimise clinical outcomes.

Conflict of interest: None

Fundings: None

Ethical approval: This study was performed in line with the principles of the Declaration of Helsinki. Approval was granted by the Institutional Review Committee of B.P. Koirala Institute of Health Sciences (BPKIHS), Dharan (Ref. No. 187-081-82),

Clinical trial number: not applicable

Human Ethics and Consent to Participate declarations: Not applicable

ACKNOWLEDGEMENT

The authors sincerely thank Prof. Dr. Ashish Shrestha, Head of the Department of Public Health Dentistry, and Prof. (Additional) Dr. Iccha Kumar Maharjan, Head of the Department of Oral Medicine and Radiology, for their valuable guidance and support during this study.



REFERENCES

1. Leblebicioglu B, Rawal S, Mariotti A. A review of the functional and esthetic requirements for dental implants. *J Am Dent Assoc.* 2007;138(3):321-329. [[PubMed](#) | [Full Text](#) | [DOI](#)]
2. Dhruvakumar D, Gupta C. Role of combination therapy/composite graft in periodontal regeneration: a mini review. *Tanta Dent J.* 2017;14(4):169-172. [[Full Text](#) | [DOI](#)]
3. Titsinides S, Agrogiannis G, Karatzas T. Bone grafting materials in dentoalveolar reconstruction: a comprehensive review. *Jpn Dent Sci Rev.* 2019;55(1):26-32. [[PubMed](#) | [Full Text](#) | [DOI](#)]
4. Brugnami F, Caiazzo A, Leone C. Local intraoral autologous bone harvesting for dental implant treatment: alternative sources and criteria of choice. *Keio J Med.* 2009;58(1):24-28. [[PubMed](#) | [Full Text](#) | [DOI](#)]
5. Koo H, Hwang J, Choi BJ, Lee JW, Ohe JY, Jung J. Comparison of vertical bone resorption following various types of autologous block bone grafts. *Maxillofac Plast Reconstr Surg.* 2023;45(1):38. [[PubMed](#) | [Full Text](#) | [DOI](#)]
6. Sakkas A, Wilde F, Heufelder M, Winter K, Schramm A. Autogenous bone grafts in oral implantology—is it still a “gold standard”? A consecutive review of 279 patients with 456 clinical procedures. *Int J Implant Dent.* 2017;3:1-17. [[PubMed](#) | [Full Text](#) | [DOI](#)]
7. Reininger D, Cobo-Vázquez C, Monteserín-Matesanz M, López-Quiles J. Complications in the use of the mandibular body, ramus and symphysis as donor sites in bone graft surgery: a systematic review. *Med Oral Patol Oral Cir Bucal.* 2016;21(2):e241-e249. [[PubMed](#) | [Full Text](#) | [DOI](#)]
8. Misch CM. Comparison of intraoral donor sites for onlay grafting prior to implant placement. *Int J Oral Maxillofac Implants.* 1997;12(6):767-776. [[PubMed](#)]
9. Toscano N, Shumaker N, Holtzclaw D. The art of block grafting: a review of the surgical protocol for reconstruction of alveolar ridge deficiency. *J Implant Adv Clin Dent.* 2010;2(2):45-66. [[Full Text](#)]
10. Misch CM. Use of the mandibular ramus as a donor site for onlay bone grafting. *J Oral Implantol.* 2000;26(1):42-49. [[PubMed](#) | [Full Text](#) | [DOI](#)]
11. Misch CM. Ridge augmentation using mandibular ramus bone grafts for the placement of dental implants: presentation of a technique. *Pract Periodontics Aesthet Dent.* 1996;8(2):127-135. [[PubMed](#)]
12. Khoury F, Hanser T. Mandibular bone block harvesting from the retromolar region: a 10-year prospective clinical study. *Int J Oral Maxillofac Implants.* 2015;30(3):688-697. [[PubMed](#) | [Full Text](#) | [DOI](#)]
13. Leong DJM, Li J, Moreno I, Wang HL. Distance between external cortical bone and mandibular canal for harvesting ramus graft: a human cadaver study. *J Periodontol.* 2010;81(2):239-243. [[PubMed](#) | [Full Text](#) | [DOI](#)]
14. Bayram F, Göçmen G, Özkan Y. Evaluating risk factors and complications in mandibular ramus block grafting: a retrospective cohort study. *Clin Oral Investig.* 2024;28(4):226. [[PubMed](#) | [Full Text](#) | [DOI](#)]
15. Kämmerer PW, Heimes D, Hartmann A, et al. Clinical insights into traumatic injury of the inferior alveolar and lingual nerves: a comprehensive approach from diagnosis to therapeutic interventions. *Clin Oral Investig.* 2024;28(4):216. [[PubMed](#) | [Full Text](#) | [DOI](#)]
16. Stoyanov H, Deliverska E. Preoperative CBCT assessment of donor site-symphysis and ramus buccal shelf for alveolar ridge augmentation. *J IMAB.* 2018;24(1):1909-1913. [[Full Text](#) | [DOI](#)]
17. Capelli M. Autogenous bone graft from the mandibular ramus: a technique for bone augmentation. *Int J Periodontics Restorative Dent.* 2003;23(3):277-286. [[PubMed](#) | [Full Text](#)]
18. Guimarães GMMDF, Bernini GF, Grandizoli DK, et al. Evaluation of bone availability for grafts in different donor sites through computed tomography. *J Appl Oral Sci.* 2020;28:e20190435. [[PubMed](#) | [Full Text](#) | [DOI](#)]
19. Sittitavornwong S, Gutta R. Bone graft harvesting from regional sites. *Oral Maxillofac Surg Clin North Am.* 2010;22(3):317-330. [[PubMed](#) | [Full Text](#) | [DOI](#)]
20. Bagourd T, Varazzani A, Dugast S, Guyonvarc'h P, Corre P, Bertin H. Radiological evaluation of inferior alveolar nerve displacement after removal of impacted mandibular third molars prior to sagittal split osteotomy. *J Stomatol Oral Maxillofac Surg.* 2023;124(6):101658. [[PubMed](#) | [Full Text](#) | [DOI](#)]