

Complex Anatomy in Endodontics: A Non-surgical Management of Vertucci Type V Canal Configuration

Aastha Neupane,¹ Reema Joshi,² Asha Thapa³

¹⁻³Conservative Dentistry and Endodontics Unit, Dental Department, National Academy of Medical Sciences, Bir Hospital, Mahabouddha, Kathmandu, Nepal

Correspondence :

Aastha Neupane. Email: drneupaneaastha09@gmail.com

ABSTRACT

Successful endodontic therapy depends on a thorough understanding of root canal anatomy and its variations. Although mandibular incisors are traditionally considered to contain a single canal, numerous studies have reported the presence of two canals with varying configurations. Among these, the Vertucci Type V configuration, where a single canal divides into two separate canals with distinct apical foramina, presents a diagnostic and clinical challenge and may result in treatment failure if the additional canal is not identified. This case report describes the diagnosis and nonsurgical endodontic management of a Vertucci Type V canal configuration in a mandibular right central incisor of a 20-year-old male patient who presented with pain in the lower anterior region. Clinical examination revealed tenderness to percussion, Grade II mobility, and the presence of a sinus opening. Radiographic examination demonstrated a periapical radiolucency with a “fast break” in the canal space suggestive of canal bifurcation. Cone beam computed tomography confirmed a single canal leaving the pulp chamber and dividing into two canals with separate apical foramina. Root canal treatment was performed under dental operating microscope, and both canals were negotiated, prepared, and obturated. A six-month follow-up radiograph showed satisfactory periapical healing. This case highlights the importance of careful radiographic evaluation, CBCT imaging, and magnification in detecting complex root canal morphology and achieving predictable endodontic outcomes.

Keywords: Cone beam computed tomography; mandibular incisor; root canal anatomy; root canal treatment; Vertucci type V.

INTRODUCTION

A clear and comprehensive understanding, along with accurate visualization, of the internal anatomy of the root canal system is essential for successful endodontic treatment, as many complications during and after the procedure arise from inadequate knowledge of pulp space anatomy, often leading to missed canals when clinicians fail to recognize their presence due to limited understanding of root canal morphology or insufficient experience in negotiating the canal.^{1,2} The studies on the internal and external anatomy of teeth have shown that anatomic

variations can occur in all groups of teeth and can be extremely complex.¹ Mandibular incisors were traditionally considered to have a single root canal. However, studies have documented high variation in root canal morphology among mandibular anterior teeth. The study on the root canal morphology

Citation

Neupane A et al. Complex Anatomy in Endodontics: A Non-surgical Management of Vertucci Type V Canal Configuration. J Nepal Dent Assoc. 2025 Jan-Jun;25(40):57-62.

This is an open access journal, and articles are distributed under the terms of the Creative Commons Attribution CC BY 4.0 Licence.

© 2025 JNDA | Published by Nepal Dental Association

of extracted mandibular incisors has reported a prevalence of two canals in 12–35% of the cases.³ Moreover, the statistical variance in mandibular incisor anatomy, with two canals reported in 11% to 68% of cases, highlights a profound morphological diversity driven largely by genetic and racial influences.^{1,4,5} Clinically, most bifurcated systems merge, as Miyashita et. al. found only 3% possess truly separate apical foramina.⁴ This complexity explains frequent endodontic failure complicating treatment and outcomes when hidden lingual canals are missed. Predictable outcomes, therefore, require magnification and angled radiographs to identify and debride these intricate anatomical variations. The purpose of this case report is to present the diagnosis and successful non-surgical endodontic management of a mandibular incisor with Vertucci Type V canal configuration, highlighting the role of CBCT and magnification in identifying complex root canal anatomy.

CASE REPORT

A 20-year-old male patient visited the Conservative Dentistry and Endodontics Unit of Bir Hospital complaining of pain in the lower front tooth for one year. The pain was gradual in onset, intermittent, dull aching, non-radiating, aggravated on biting, and relieved on its own or sometimes on taking a painkiller. There was no history of night pain or pain on lying down. He also gives a history of burning sensation and pain while having hot food in the same area of complain five years back, for which he didn't seek any medical advice. The pain was not associated with swelling, gingival bleeding, and food lodgement. There was no contributory medical and dental history, as well as known drug allergy. He was a non-smoker, non-alcoholic, and did not have any deleterious habits like nail biting, tongue thrusting, bruxism, and clenching.

Intraoral examination revealed Grade II mobility (Miller's classification of tooth mobility) in relation to tooth #41 (FDI numbering system). The tooth was tender to vertical percussion. The periodontal

pocket depth was 3mm. A sinus opening was present on the labial gingiva. There were no visible cracks, fracture and bleeding on probing. However, on examination of the occlusion, a traumatic bite was noticed. On pulp neural sensibility testing (Electric pulp test and cold test), there was no response. Intraoral periapical radiograph was chosen as the primary line of investigation, which revealed intact coronal tooth structure with apical root resorption in relation to tooth #41. There was a widening of the periodontal ligament space with loss of lamina dura. On an intraoral periapical radiograph, a well-defined radiolucency measuring approximately 3mm×2mm was seen in the periapical region. The pulp canal space showed a fast break of a wide pulp canal from the middle one-third of root to the apex. Further evaluation was done by cone beam computed tomography. The axial view revealed loss of buccal cortical plate with the presence of well-defined hypo attenuation in the apical region, which was 6.11 mm labio-palataly (with loss of labial cortical plate and intact lingual cortical plate), 5.33 mm mesio-distally, and 7.72 mm supero-inferiorly. Sagittal view showed canal morphology, which revealed one canal leaving the chamber and dividing into two separate canals with separate apical foramina [Vertucci type V (1-2)]. Root resorption was also noticed apically. Based on these findings, a diagnosis of necrotic pulp with chronic periapical abscess in relation to tooth #41 was made. Immediate occlusal relief followed by non-surgical endodontic therapy was established as a treatment plan.

The patient was informed about the treatment procedure and its prognosis. Then, the consent was taken. Selective grinding of tooth was done to relieve a traumatic bite. Inferior alveolar nerve block was given, and tooth was isolated with a rubber dam. Under magnification of 20x (Labomed Magna dental operator microscope), access cavity preparation was done using a round diamond bur at high speed. Canal troughing was done with the help of an ultrasonic tip ED4D. At first, a straight labial

canal was negotiated then, following removal of the lingual shoulder with the help of an ultrasonic tip, the lingual orifice was located. After achieving canal patency, the working length was determined by the #10k file. The working length of 18 mm in the labial canal and 19mm in the lingual canal was obtained, that have been confirmed by the electronic apex locator and intraoral periapical radiograph. Biomechanical preparation was done with crown-down technique using rotary file system Hyflex CM by Coltene upto #25/4% taper. Disinfection was done with 3% sodium hypochlorite and normal saline. The final irrigation was done with 17% ethylenediaminetetraacetic acid. Activation of irrigating solution was done using a number 25 U

file for 20 seconds in each canal. After drying the canals with absorbent paper points, the master cone fit (Gutta percha from Coltene with 4% taper) was checked and confirmed by an intraoral periapical radiograph. Master cone and accessory cones were disinfected by dipping in sodium hypochlorite for 1 minute, followed by dipping the cones in normal saline for the next 1 minute. Obturation was done with gutta percha and bioceramic sealer (Safe Endo) by the cold lateral compaction technique. Post-obturation radiograph was taken before the patient leaves the operatory, and follow-ups of 1 month, 3 months, 6 months, and 1 year were kept. The six-months follow-up radiographs showed healing of the periapical area.

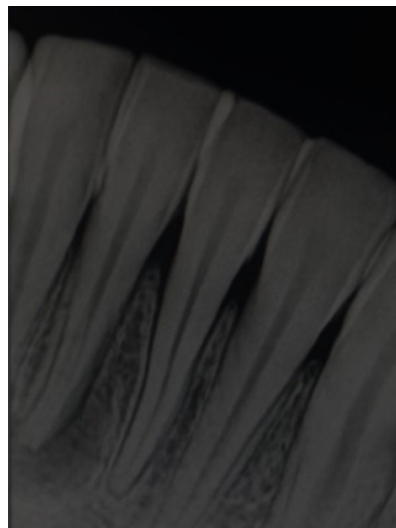


Figure 1: Intraoral periapical radiograph of tooth #41 showing fast break in middle third of the root

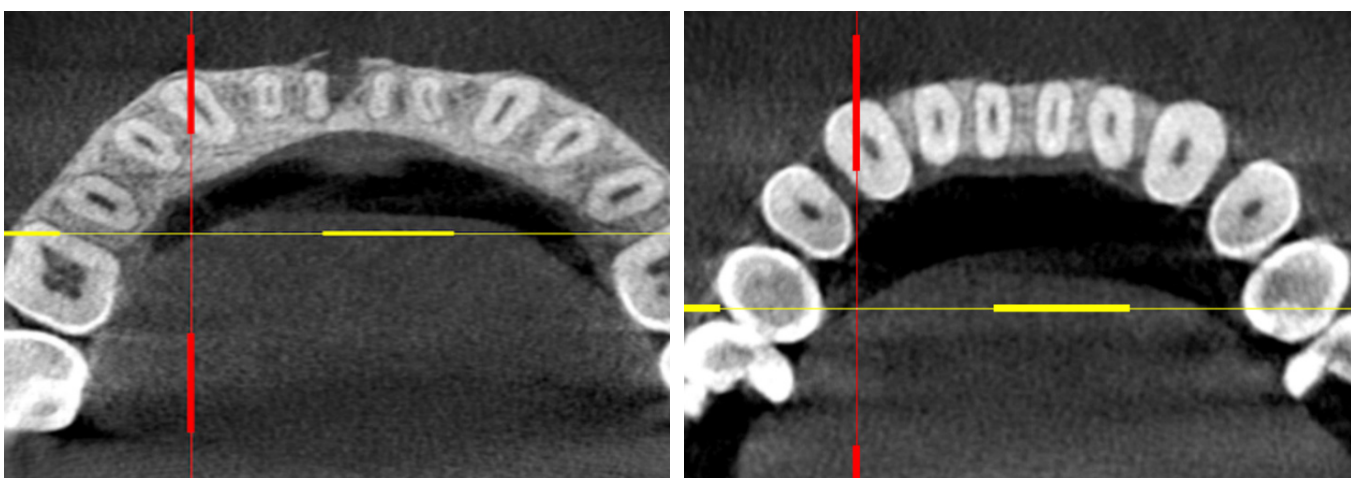


Figure 2: Axial view showing canal opening in pulp chamber and bifurcation of canal

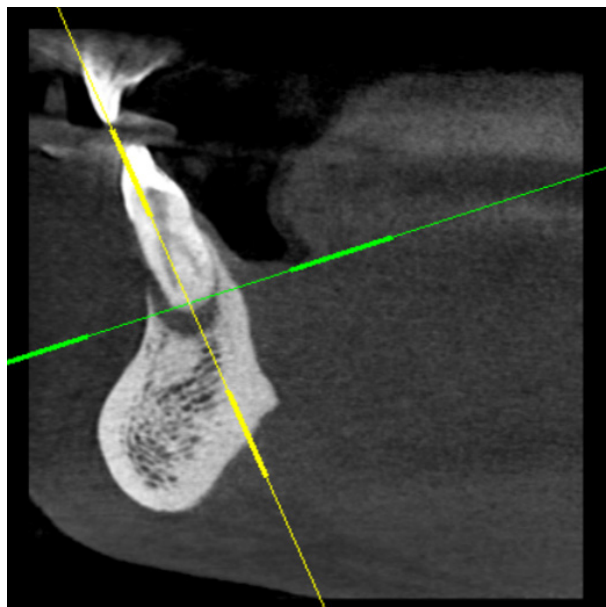


Figure 3: Sagittal view showing canal bifurcation in middle third of root, slight resorption and loss of buccal cortical plate.

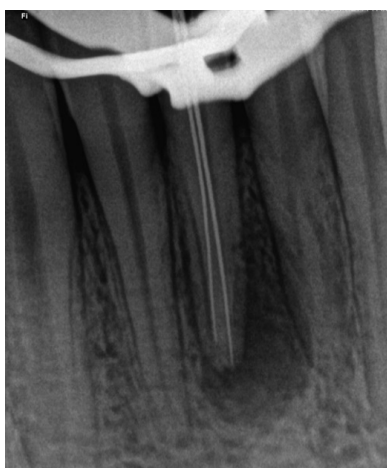


Figure 4 : Working length radiograph

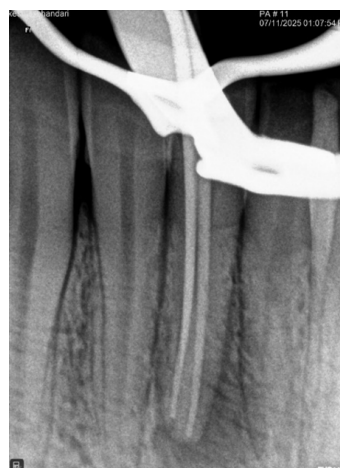

Figure 5: Master-cone fit radiograph

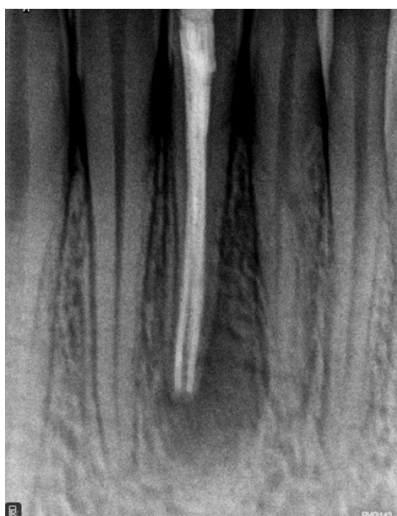


Figure 6: Post obturation intraoral periapical radiograph.

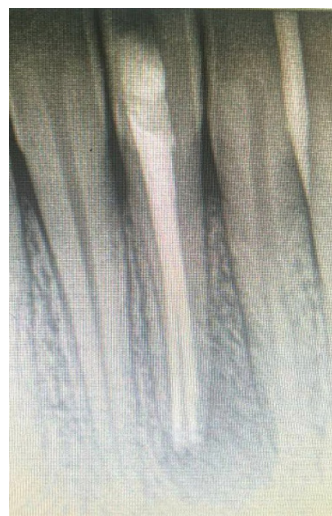

Figure 7: Follow up radiograph of 6 months.

DISCUSSION

Successful endodontic therapy depends on the practitioner's ability to locate, clean, shape, and seal the entire root canal system. A thorough understanding of anatomical variations is essential, particularly when encountering a "deep split" or Vertucci Type V configuration. This challenging morphology, where a single canal leaves the pulp chamber but divides into two separate canals and foramina in the apical third, requires precise diagnosis and specialized management.⁶

The mandibular anterior teeth are not frequently cariously involved, but there are many situations where these teeth require endodontic treatment. In order to ensure endodontic success, clinicians should consider the vital role of understanding normal anatomy and common variations, careful interpretation of angled radiographs, use of three-dimensional imaging (cone beam computed tomography), proper access cavity preparation, and detailed exploration of the interior of the tooth, ideally under magnification.^{4,6} To manage these intricate systems, the dental operating microscope (DOM) has become the gold standard, providing superior illumination and magnification that allow clinicians to visualize anatomical landmarks like the dentinal map and spot hidden orifices with greater precision. The improved ability to see specific canals helps clinicians achieve better instrumentation of canal openings with greater efficiency. By direct visualization alone, it is not possible to confirm whether all canals have been adequately instrumented without removing excessive coronal tooth structure.⁷

Diagnosis of such bifurcations often depends on the "fast break" radiographic rule, where a sudden change in radiographic density or the disappearance of a pulp space indicates canal division. If a radiograph reveals a wide apical root portion rather than a tapering, narrow one, a bifurcation or trifurcation should be suspected. Tactile sensation, in many cases, can be the only way to diagnose bifurcation. If the apex locator shows confused

readings and two different working length readings in the same canal, this could indicate bifurcation.⁸

This case reflects the complexities described by Kokane et al., where endodontic failure in mandibular incisors was directly attributed to the inability to detect a second lingual canal.² Similar to their findings, identifying these canals often requires extending access preparations incisogingivally and removing the "lingual shelf" of dentin that frequently shields the lingual orifice. The lingual aspect of the pulp chamber should be opened with a round bur below the gingival margin. Once adequate access has been achieved, the instruments should be curved slightly to engage the lingual aspect of the canal.⁸ Hernawatiningsih et al. suggested that once the split is negotiated, techniques such as warm vertical condensation are the treatment of choice to ensure a three-dimensional seal of the variable apical anatomy.⁶ In contrast, this case report utilizes cold lateral compaction as the obturating technique. Rankine et al. highlighted that the presence of an unfilled lingual canal is a primary driver of failure, necessitating modified access and curved instruments to effectively engage the lingual aspect.⁹

The successful healing of the periapical lesion observed at the six-month follow-up in the present case indicates that accurate diagnosis, careful canal negotiation, and proper endodontic procedures can effectively manage teeth with complex canal morphology without the need for surgical intervention. This case, therefore, emphasizes the importance of thorough radiographic evaluation, the use of CBCT when necessary, and the application of magnification to enhance the clinician's ability to detect and treat anatomical variations.

SUMMARY

This case report describes the non-surgical endodontic management of a mandibular central incisor with a Vertucci Type V canal configuration. Accurate three-dimensional diagnosis of canal bifurcation using cone beam computed tomography,

combined with magnification provided by a dental operating microscope, enabled precise localization and treatment of both canals, resulting in favorable periapical healing at follow-up.

Conflict of Interest: None



REFERENCES

1. Vertucci F. Root canal morphology and its relationship to endodontic procedure. *Endodontic Topics*. 2005 March; 10:3-29. [[Full Text](#) | [DOI](#)]
2. Kokane VB, Patil SN, Gunwal MK, et al. Treatment of two canals in all mandibular incisor teeth in the same patient. *Case Reports in Dentistry*. 2014;2014(1):893980. [[PubMed](#) | [Full Text](#) | [DOI](#)]
3. Al-Fouzan K, Al-Rejaie M, AlManee A, et al. Incidence of two canals in extracted mandibular incisors teeth of Saudi Arabian samples. *Saudi Endodontic Journal*. 2012;2:65. [[Full Text](#)]
4. Miyashita M, Kasahara E, Yasuda E, et al. Root canal system of the mandibular incisor. *Journal of Endodontics*. 1997 August;23(8):479-84. [[PubMed](#) | [Full Text](#) | [DOI](#)]
5. Sert S, Aslanalp V, Tanalp J. Investigation of the root canal configurations of mandibular permanent teeth in the Turkish population. *International Endodontic Journal*. 2004 July;37(7):494-99. [[PubMed](#) | [Full Text](#) | [DOI](#)]
6. Hernawatiningsih, Kristanti Y, Subandhi D. Root canal treatment on Vertucci type V configuration – A Case Report. 2021. [[Full Text](#) | [DOI](#)]
7. Arora A, Kaur H, Gupta I. Magnification in endodontics: A review. *International journal of health sciences*. 2021 July:193-202. [[Full Text](#) | [DOI](#)]
8. Aggarwal K. Mandibular lateral incisor with Vertucci type IV root canal morphological system: A rare case report. *J Nat Sci Biol Med*. 2016 June;7(1):101-4. [[PubMed](#) | [Full Text](#)]
9. Rankine-Wilson RW, Henry P. The bifurcated root canal in lower anterior teeth. *The Journal of the American Dental Association*. 1965 May;70(5):1162-5. [[PubMed](#) | [Full Text](#) | [DOI](#)]