

# Conservative Management of Temporomandibular Disorder with Occlusal Splints: Case series

Luna Ghimire,<sup>1</sup> Sushma Paudel,<sup>2</sup> Sunanda Sundas,<sup>3</sup> Amita Rai,<sup>4</sup> Tripti Lath<sup>5</sup>

<sup>1,2</sup>Post-graduate Resident, Department of Pediatric and Preventive Dentistry, People's Dental College and Hospital, Sorhakhutte, Kathmandu, Nepal.

<sup>3</sup>Professor and Head, Department of Pediatric and Preventive Dentistry, People's Dental College and Hospital, Sorhakhutte, Kathmandu, Nepal.

<sup>4,5</sup>Assistant Professor, Department of Pediatric and Preventive Dentistry, People's Dental College and Hospital, Sorhakhutte, Kathmandu, Nepal.

Correspondence :

Luna Ghimire. Email: [lunaghimire1259@gmail.com](mailto:lunaghimire1259@gmail.com)

## ABSTRACT

The temporomandibular joint (TMJ) connects the mandible to the skull. Dysfunction of TMJ may cause pain, difficulty in chewing, additional sounds, and even locking of jaws. American Academy of Orofacial Pain defines temporomandibular disorder (TMD) as a combined term of clinical problems that involve the masticatory musculature, the TMJ, and its associated structures. Multiple factors like bruxism, psychological factors, trauma, excessive mouth opening, faulty restorations etc. contribute to TMD. Occlusal splint is one of the conservative modalities to manage TMD. It is less invasive, and it also provides balanced occlusal contacts without altering mandibular rest position. In the present case series, three cases of TMD were successfully managed with occlusal splints.

**Keywords:** Conservative management; occlusion; occlusal splint; temporomandibular joint; temporomandibular joint disorder.

## INTRODUCTION

The stomatognathic system comprises of the neuromuscular structures, the temporomandibular joints (TMJs), and the teeth. For optimal long-term function and health, all components of the stomatognathic system must work in harmony.<sup>1-3</sup> When any of these elements is compromised, it disrupts this balance, which ultimately initiates a chain of dysfunction that leads to temporomandibular joint disorders (TMDs).<sup>4</sup> In children, occlusal derangements are often detected early during clinical examination. However, temporomandibular joint (TMJ) alterations usually

remain asymptomatic and are often identified only through imaging. Therefore, relying solely on clinical signs may delay the early diagnosis of TMD. Therefore, timely diagnosis and treatment are essential to address the patient's symptoms, which ultimately helps to preserve long-term stomatognathic health.<sup>5</sup>

### Citation

Ghimire L et al. Conservative Management of Temporomandibular Disorder with Occlusal Splints: Case series. *J Nepal Dent Assoc.* 2025 Jan-Jun;25(40):63-9.

This is an open access journal, and articles are distributed under the terms of the Creative Commons Attribution CC BY 4.0 Licence.

© 2025 JNDA | Published by Nepal Dental Association

Multiple factors like bruxism, psychological factors, trauma, excessive mouth opening, faulty restorations etc. contribute to TMD. The prevalence of TMD in adolescents ranges from 7.3-30.4%, and females more commonly affected as compared to males (44.7% vs. 30%).<sup>6,7</sup> Common clinical presentations of TMD are pain radiating to the head, neck, or shoulders; headaches; tinnitus; jaw deviation; jaw locking; and restricted opening.

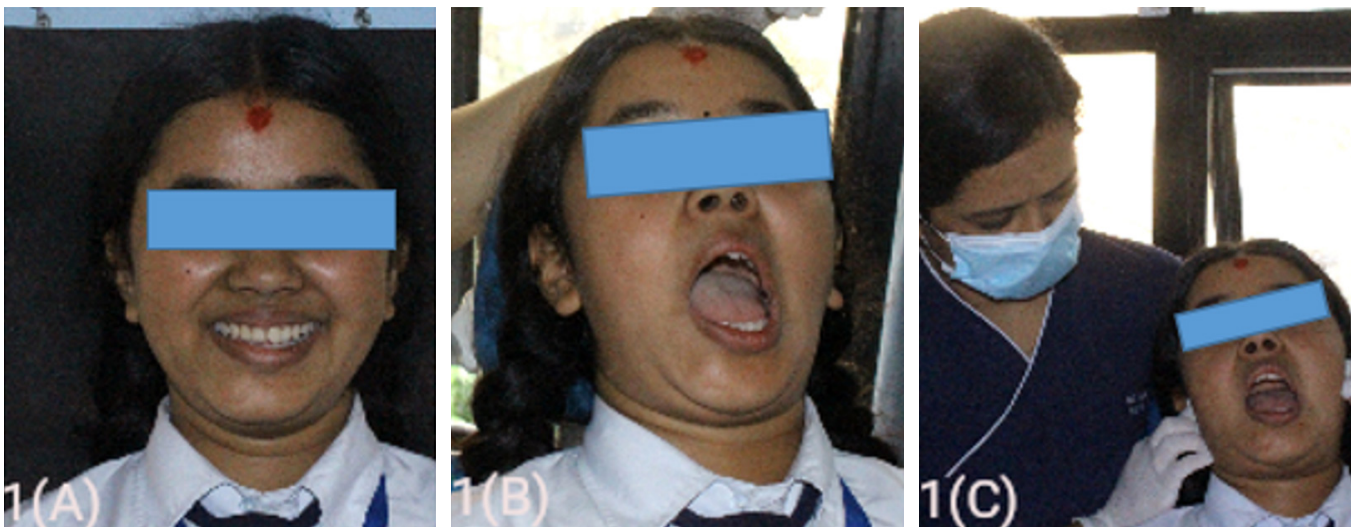Common modalities for the management of TMD include patient counseling, physiotherapy, warm compresses, occlusal adjustments, occlusal splints, pharmacotherapy, and psychotherapeutic support supplemented by adjunctive methods like acupuncture, ultrasound, and low-level laser therapy.<sup>8,9</sup> According to the American Academy of Pediatric Dentistry (AAPD), conservative therapies should be the first-line treatment for TMD in children and adolescents.<sup>10</sup> Provision of occlusal splints in TMD allows the occlusion to stay in rest position, thus relieving occlusal load.<sup>11</sup> The present case series highlights the effectiveness of occlusal splint therapy in managing TMD-related pain in three adolescent female patients.

## CASE PROPER

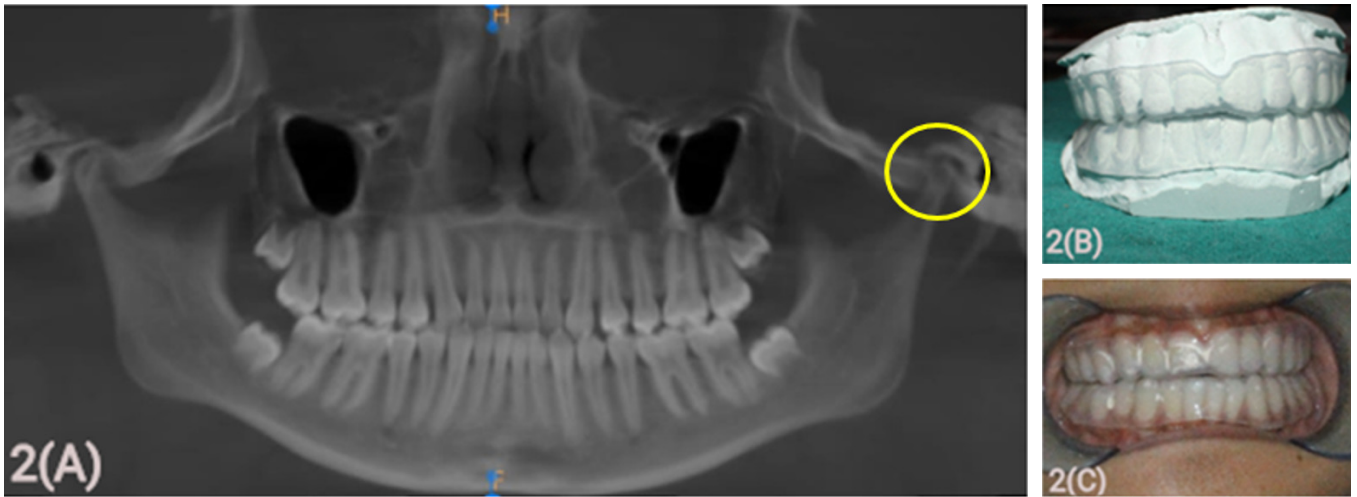
### Case I:

A 13-year-old female presented to the Department with the complaint of discomfort in the left periauricular area for five months. There was also a history of unilateral headache, mental stress, and nasal blockage. There was no history of traumatic injury to head, neck or jaw region. The patient had been taking analgesics for one year with only temporary relief.

On a clinical assessment, there was unilateral clicking sound on left side, and the patient was unable to open her mouth beyond 35 mm. Deflection was noted towards the left side during mouth opening (Figure 1A, 1B). Muscles of mastication were non-tender, and there was no crepitus on either of sides of TMJ (Figure 1C). Cone Beam Computed Tomography (CBCT) revealed that the left condyle was angular in shape with mild osteoarthritic degenerative changes. There was mild erosion on the antero-superior surface of the condyle, and flattening of the head of the condyle (Figure 2A). Based on the history and clinical examination, diagnosis of Temporomandibular joint disorders due to degenerative changes was made.



**Figure 1: 1(A, B, C): Extra-oral examination revealing deflection towards the left side.**



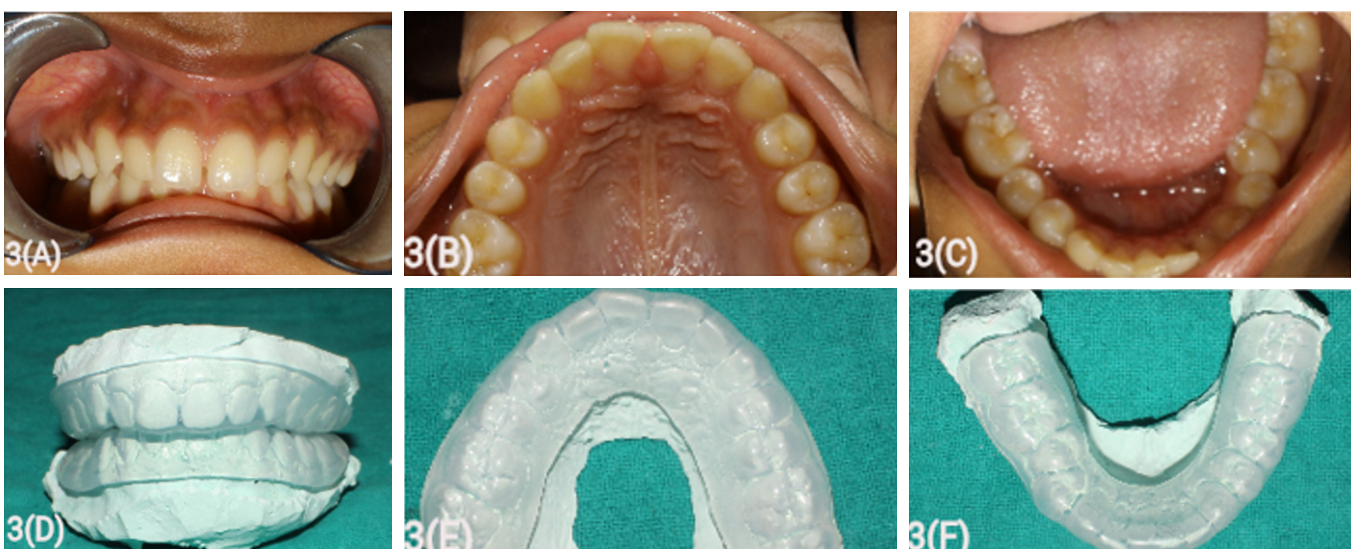
**Figure 2: 2(A): CBCT revealing mild erosion on the antero-superior surface of the condyle, and flattening of the head of the condyle; 2(B): Fabrication of occlusal splints; 2(C): Insertion of occlusal splints.**

**Case-II:**

An 11-year-old female reported to the Department with the complaint of discomfort on left periauricular area since four months. According to the patient, pain increased during mastication and yawning. Due to pain, the patient had discontinued eating hard food, and was taking analgesics. Patient was taking muscle relaxant (Cyclobenzaprine) for past five months.

On a clinical examination, there was unilateral

clicking sound on left side, and the patient was unable to open her mouth beyond 30 mm. Muscles of mastication were non-tender, and there was no crepitus. Detailed evaluation of TMJ examination using Fonseca's Questionnaire<sup>12</sup> was done, and a score of 70 was obtained. On intraoral examination, anterior deep bite was present (Figure 3A, 3B, 3C). Based on the history and clinical examination, diagnosis of left temporomandibular joint disc displacement with reduction associated with TMJ arthralgia was made.



**Figure 3: 3(A): Intraoral frontal view; 3(B): Maxillary occlusal view; 3(C): Mandibular occlusal view; 3(D, E, F): Fabrication of thermo-plasticized occlusal splints.**

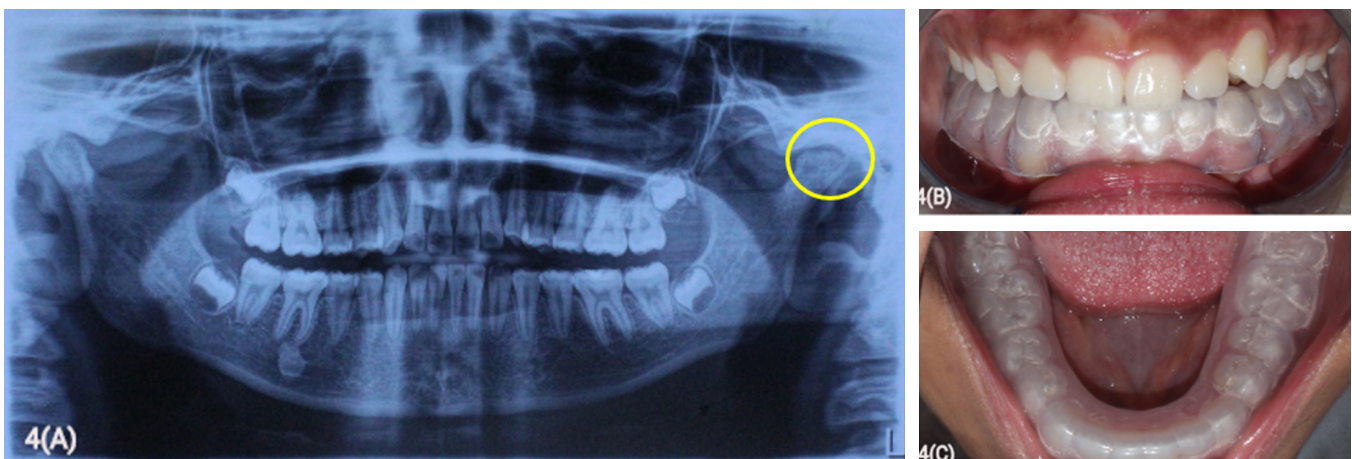
### Case-III

A 12-year-old female reported with the complaint of discomfort on left periauricular area since three months. The patient also complained of unilateral headache and discomfort. There was no history of traumatic injury to head, neck or jaw region. The patient had been taking analgesics for six months. Patient was under medication for muscle relaxation (Cyclobenzaprine) for the past two months.

On a clinical assessment, unilateral clicking sound was noted on the left side, and she was unable to open her mouth beyond 32 mm. There was presence of tenderness of masseter, temporalis and medial and lateral pterygoid muscles on left side. On intra-oral examination, occlusion was intact. Orthopantomogram (OPG) revealed that left condyle was angular in shape with mild osteoarthritic degenerative joint changes, and flattening of head of the condyle (Figure 4A). Based on the history and clinical examination, diagnosis of Temporomandibular joint disorders due to osteoarthritic degeneration was made.

Conservative management with occlusal splint therapy was planned in all the three cases. Informed consent and assent were obtained from the patient parties for the same. For fabrication of occlusal splint, impressions of the maxillary and mandibular arches were made using alginate impression material (Prevest Denpro, Prevest Denpro Limited, India).

Then, type III orthodontic stone (Orthokal, Kalabhai Karson Pvt. Limited, India) was used to pour the impressions. Retrieved models were then placed in vacuum forming machine, and thermoplastic sheets of 1.5 mm thickness were adapted on the casts. The splint was trimmed, and borders smoothed so as to avoid any impingement of the appliance to the soft tissue. It was further adjusted in the patient's oral cavity. The patients were instructed to wear the appliance maximum time except for eating, drinking hot food and brushing teeth. Patients were also advised to perform muscle exercises like the relaxed jaw exercise, controlled mouth opening exercise, resisted mouth opening and closing exercises after consulting with physiotherapist for 10-15 minutes/day. The patients were advised not to open their mouth too wide while eating, and to support the jaw while yawning. Post-therapy sign and symptoms were analyzed according to fonseca's questionnaire<sup>12</sup> for TMD over three days, one month, and three months follow-up visits in all the three cases, which revealed the decrease in scores. On the follow-up visit at four months, all the signs and symptoms were reduced, and there was progressive reduction of masseter muscle mass. The patients also reported that they had discontinued the medications they had been taking. In the second case, there was anterior deep bite malocclusion. So, once occlusion was stabilized, the patient was referred for orthodontic treatment.



**Figure 4: 4(A): OPG showing flat left condyle and mild osteoarthritic degenerative joint changes; 4(B, C): Insertion of occlusal splint.**

## DISCUSSION

The goal of appliance therapy is to provide orthopedic stability to the TMJ, and alter the occlusion temporarily to decrease parafunctional activity and pain. The design of the splint plays a crucial role in its effectiveness. A flat posterior surface touching only supporting cusp tips minimizes the stimulation of periodontal proprioceptors which can provoke muscular hyperactivity. It also allows the condyles to be seated in the most antero-superior position progressively, facilitating joint healing and adaptation.<sup>3</sup>

Various alternative treatments like physiotherapy, localized steam application, external muscle massage, occlusal adjustment, analgesics, psychotropic medication, acupuncture, ultrasound, soft laser, diathermy and infrared radiation have been tried to manage TMD.<sup>13</sup> Orthodontic treatment is advised after TMD symptoms are controlled and occlusion is stabilized through splints, therapy or restorative work. Surgical intervention is considered a last resort, as most TMD cases respond well to non-invasive therapies such as splints, physiotherapy, and behavioral therapy.<sup>14</sup> In the present case series, we opted for a soft thermoplastic occlusal splint because it permits continued eruption of teeth, and is less likely to interfere with growth. The patients experienced significant relief from symptoms almost immediately after the insertion of the appliances. A patient with malocclusion was referred for orthodontic treatment once the initial symptoms subsided.

Occlusal splints are widely accepted modality in the management of TMDs. Occlusal splints reduce pain and restricts jaw movements. Splints can be fabricated from materials like acrylic resin (hard splints) or polyacetamide thermoplastic sheets (soft splints). The primary objectives of the occlusal splints are to protect the TMJ discs from dysfunctional forces, and improve jaw muscle function, thereby establishing harmonious occlusion and reducing associated symptoms.<sup>15</sup> Reduction in joint and muscle pain, and improved mouth

opening can be attributed to the patient's adherence to the prescribed therapy and regular follow-up visits. This emphasizes the importance of patient compliance in achieving favorable outcomes.

Multiple studies and evidence support and advocate use of occlusal splints.<sup>16,17,18,19,20,21</sup> The American Academy of Orofacial Pain (AAOP) also supports reversible approaches such as occlusal splints, physiotherapy, and behavioral modification as standard of care for TMD cases. The American Academy of Pediatrics (AAP) has highlighted the need for awareness of orofacial pain syndromes in children, encouraging timely referral to dental specialists.<sup>22</sup>

Another clinical point of interest is the female predilection in TMD studies (female-to-male ratios up to 2:1).<sup>7</sup> This trend was also reflected in the present case series, where all three patients were adolescent females, suggesting the influence of hormonal, psychosocial, or behavioral factors during adolescence.<sup>23</sup>

The clinical relevance of TMD extends beyond dentistry. Before the diagnosis was confirmed, patients were evaluated in collaboration with other specialties, including physiotherapist and ENT consultation. A thorough assessment was performed, and alternative causes of facial pain such as dental infections or abscesses, sinusitis, and headaches (migraine or tension-type) were excluded as TMD-related pain often overlaps with these conditions.<sup>24</sup> Early referral to dental specialists can therefore prevent chronic orofacial pain and reduce the risk of joint degeneration. Additionally, early treatment supports optimal facial and dental development during critical growth periods. Occlusal splints also provide a cost-effective alternative to more invasive procedures, offering a reversible treatment option.<sup>25</sup>

## SUMMARY

Early recognition and timely intervention for TMD are valuable, as conservative therapy may prevent progression into chronic, debilitating conditions.

For medical and dental practitioners, the present case series emphasizes the importance of including TMD in the differential diagnosis of head, neck, and facial pain, and of timely referral to dental specialists for collaborative management. This case series highlighted the conservative management of TMD with occlusal splints in adolescent patients.

## ABBREVIATIONS

TMJ	: Temporomandibular Joint
TMD	: Temporomandibular Disorder
AAPD	: American Academy of Pediatric Dentistry
CBCT	: Cone Beam Computed Tomography
3D	: Three-dimensional
OPG	: Orthopantomogram

**CONFLICT OF INTEREST:** None.



## REFERENCES

1. Alomar X, Medrano J, Cabratosa J et al. Anatomy of the temporomandibular joint. *Semin Ultrasound CT MR*. 2007 Jun;28(3):170-83. [[PubMed](#) | [DOI](#)]
2. University of Illinois Chicago College of Dentistry. Understanding TMJ disorders (TMD) [Internet]. Chicago (IL): UIC College of Dentistry; 2023 [cited on 2025 Oct 16]. [[Link](#)]
3. Chisnoiu AM, Picos AM, Popescu LM et al. Factors involved in the etiology of temporomandibular disorders: A literature review. *J Med Life*. 2015 Nov 15;8(2):165–71. [[PubMed](#) | [Full Text](#) | [DOI](#)]
4. Chiodelli L, Pacheco AB, Missau TS, Silva AMT et al. Association among stomatognathic functions, dental occlusion and temporomandibular disorder signs in asymptomatic women. *Rev CEFAC*. 2015 Jan;17(1):117-25. [[PubMed](#) | [Full Text](#) | [DOI](#)]
5. Conti ACCF, Oltramari PVP, Navarro RL et al. Examination of temporomandibular disorders in the orthodontic patient: a clinical guide. *J Appl Oral Sci*. 2007 Feb;15(1):77-82. [[PubMed](#) | [Full Text](#) | [DOI](#)]
6. Christidis N, Lindstrom Ndanshau E, Sandberg A et al. Prevalence and treatment strategies regarding temporomandibular disorders in children and adolescents – a systematic review. *J Oral Rehabil*. 2019 Mar;46(3):291-301. [[PubMed](#) | [DOI](#)]
7. Minervini G, Franco R, Marrapodi MM et al. Prevalence of temporomandibular disorders in children and adolescents evaluated with Diagnostic Criteria for Temporomandibular Disorders: A systematic review and meta-analysis. *J Oral Rehabil*. 2023 Sep;50(6):522-30. [[PubMed](#) | [Full Text](#) | [DOI](#)]
8. Warzocha J, Szyszka-Sommerfeld L, Smiech A et al. Etiologic Factors of Temporomandibular Disorders: Systematic Review. *Healthcare (Basel)*. 2024 Feb 29; 12(5):575. [[PubMed](#) | [Full Text](#) | [DOI](#)]
9. Sood R, Sharma S, Sood S et al. Effectiveness of non-invasive physiotherapy techniques in temporomandibular disorders: A systematic review. *J Oral Maxillofac Surg Med Pathol*. 2025 Jun 25;37(1):1-10. [[Full Text](#)]
10. American Academy of Pediatric Dentistry. Temporomandibular disorders in children and adolescents, including those with special health care needs. *The Reference Manual of Pediatric Dentistry*. Chicago, Ill.: American Academy of Pediatric Dentistry; 2024:494-504. [[Link](#)]
11. Ainoosah SA, Al-Bargi H, Al-Shahrani M et al. Comparative analysis of different types of occlusal splints: A systematic review. *J Prosthet Dent*. 2024 Jan 5;132(1):1-10. [[PubMed](#) | [Full Text](#) | [DOI](#)]
12. Nomura K, Vitti M, de Oliveira AS, Chaves TC et al. Use of the Fonseca's questionnaire to assess the prevalence and severity of temporomandibular disorders in Brazilian dental undergraduates. *Braz Dent J*. 2007 Oct 25;18(2):163–7. [[PubMed](#) | [Full Text](#) | [DOI](#)]
13. Seifeldin SA, Elhayes KA. Soft versus hard occlusal splint therapy in the management of temporomandibular disorders (TMDs). *Saudi Dent J* 2015;27:208-14. [[DOI](#) | [Full Text](#)]
14. Sá M, Faria C, Pozza DH. Conservative versus invasive approaches in temporomandibular disc displacement: a systematic review of randomized controlled clinical trials. *Dent J (Basel)*. 2024 Jul 31;12(8):244. [[PubMed](#) | [Full Text](#) | [DOI](#)]

15. Albagieh H. Occlusal splints: types and effectiveness in temporomandibular disorder management. *J Global Oral Health*. 2022 Jan 1;5(1):1–8. [[PubMed](#) | [Full Text](#) | [DOI](#)]
16. Zhang SH, He KX, Lin CJ et al. Efficacy of occlusal splints in the treatment of temporomandibular disorders: a systematic review of randomized controlled trials. *Acta Odontol Scand*. 2020 Nov 16;78(8):580-9. [[PubMed](#) | [DOI](#)]
17. Ram HK, Shah DN. Comparative evaluation of occlusal splint therapy and muscle energy technique in the management of temporomandibular disorders: a randomized controlled clinical trial. *J Indian Prosthodont Soc*. 2021 Oct 1;21(4):357-65. [[PubMed](#) | [Full Text](#) | [DOI](#)]
18. Riley P, Glenny AM, Worthington HV et al. Oral splints for temporomandibular disorders or bruxism: a systematic review and economic evaluation. *Health Technol Assess*. 2020 Feb;24(7):1-224. [[PubMed](#) | [Full Text](#) | [DOI](#)]
19. Giannasi LC, Santos IR, Alfaya TA et al. Effect of an occlusal splint on sleep bruxism in children in a pilot study with a short-term follow up. *J Body Mov Ther*. 2013 Oct 1;17(4):418-22. [[PubMed](#) | [DOI](#)]
20. Hussain S, Amjad A, Rehman A. Efficacy of hard and soft occlusal splint therapy in the management of temporomandibular disorders: a comparative study. *J Rehman Med Inst*. 2024 Jul-Sep;10(3):9-15. [[Full Text](#)]
21. Tomaka AA, Luchowski L, Tarnawski M et al. Computer-aided design of personalized occlusal positioning splints using multimodal 3D data. *arXiv*. 2025 April 17. [[Link](#)]
22. Sawicki CM, Sangalli L. Pediatric dentists' practice patterns in the screening, diagnosis, and management of temporomandibular disorders. *Children (Basel)*. 2024 Sep 26;11(10):1168. [[PubMed](#) | [Full Text](#) | [DOI](#)]
23. List T, Wahlund K, Larsson B. Psychosocial functioning and dental factors in adolescents with temporomandibular disorders: a case-control study. *J Oral Fac Pain*. 2001 Jul 1;15(3):218–27. [[PubMed](#) | [Full Text](#)]
24. Yakkaphan P, Elias LA, Ravindranath PT et al. Persistent orofacial pain: a narrative review. *Br Dent J*. 2024 Nov 17;236(6):475-82. [[PubMed](#) | [Full Text](#) | [DOI](#)]
25. Steve M, Rosales Leal JI. Effects of occlusal splints on temporomandibular disorders and well-being among fibromyalgia and bruxism patients: A quasi-experimental study. *Appl Sci*. 2025 Apr 18;15(8):4465. [[Full Text](#) | [DOI](#)]