

# Multidisciplinary Management of Fractured and Discolored Maxillary Anterior Tooth With Open Apex and Periapical Pathology

Manoj Raj Giri,<sup>1</sup> Asha Thapa,<sup>2</sup> Reema Joshi<sup>3</sup>

<sup>1-3</sup>Conservative Dentistry and Endodontics Unit, Dental Department, National Academy of Medical Sciences, Bir Hospital, Mahabouddha, Kathmandu, Nepal

Correspondence :

Manoj Raj Giri. Email: [giri.man2023@gmail.com](mailto:giri.man2023@gmail.com)

## ABSTRACT

Traumatic injuries to anterior teeth can result in pulp necrosis, arrested root development, and formation of an open apices thereby complicating the endodontic management. This case report describes a multidisciplinary approach for the management of a fractured maxillary anterior teeth with an open apex and associated periapical pathology. Treatment involved root canal therapy, surgical enucleation of the cystic lesion, apicoectomy with retrograde filling using bioceramic putty, thermoplasticized obturation, and intracoronal non vital bleaching. The combined use of endodontic, surgical, and esthetic procedures resulted in the favorable healing and satisfactory esthetic outcomes. Thus, this report highlights the importance of an integrated treatment strategy for managing the complex traumatic dental injuries.

**Keywords:** Bioceramic putty; non vital bleaching; open apex; periapical pathology; retrograde filling; thermoplasticized obturation.

## INTRODUCTION

Traumatic injuries to anterior teeth are frequently encountered in our day-to-day clinical practice, particularly in the younger individuals. These injuries often result in pulp necrosis, arrested root development, thereby leading to the formation of teeth with open apices and associated periapical pathology.<sup>1</sup>

In cases of persistent periapical pathology or large cystic lesions, a surgical intervention with retrograde filling is performed.<sup>2</sup> Retrograde filling with bioceramic materials such as calcium silicate-based materials have shown superior properties in terms of sealing ability, biocompatibility, and periradicular tissue regeneration.<sup>3</sup> After an apical seal or barrier, the use of thermoplasticized obturation techniques ensures a hermetic seal.<sup>4</sup> Additionally, dental trauma is often accompanied by esthetic concerns due to enamel dentin fracture

and discoloration of the tooth being non-vital. For the discoloration of a non-vital tooth, intracoronal non-vital bleaching offers a conservative and effective treatment in restoring natural tooth color and esthetics without the need for extensive restorative procedures.<sup>5</sup>

This case highlights a comprehensive and multistaged approach for managing a fractured maxillary anterior tooth with an open apex and periapical pathology, employing retrograde filling, thermoplasticized gutta-percha obturation, and non-vital bleaching to restore both function and esthetics.

### Citation

Giri MR et al. Multidisciplinary Management of Fractured and Discolored Maxillary Anterior Tooth With Open Apex and Periapical Pathology. *J Nepal Dent Assoc.* 2025 Jan-Jun;25(40):51-6.

This is an open access journal, and articles are distributed under the terms of the Creative Commons Attribution CC BY 4.0 Licence.

© 2025 JNDA | Published by Nepal Dental Association

## CASE REPORT

A 19-year-old male patient reported to the Conservative Dentistry and Endodontics Unit with the chief complaint of swelling in the upper front teeth region. The patient gave a history of trauma to the maxillary anterior teeth 11 years ago. Clinical examination revealed fracture of tooth 11 and fracture with discoloration of tooth 21, along with a sinus opening in relation to tooth 21.

The swelling was present in the palatal region, which appears to be approximately 1.5 to 2 cm in diameter, extending anteroposteriorly from the incisive papilla region toward the mid-hard palate, and mediolaterally confined within the midline. Also, the swelling was soft and fluctuant in nature.

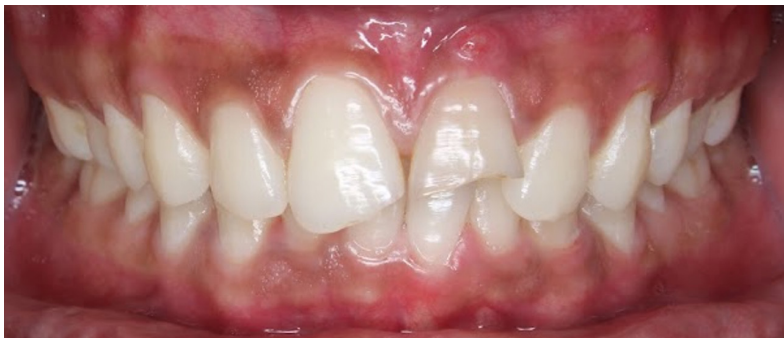Pulp sensibility test showed normal response in

relation to 12, 11, 22, 23, 24 and no response was observed in relation to 21.

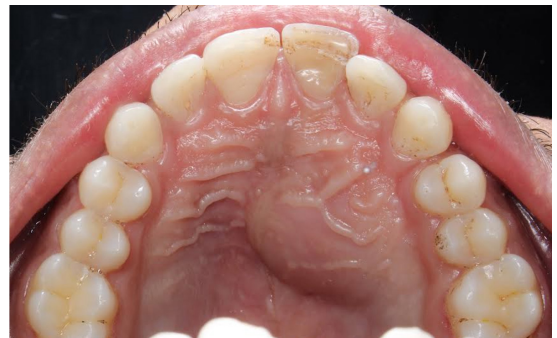## RADIOGRAPHIC EXAMINATION

Initially, an intraoral periapical radiograph (IOPAR) was taken followed by a cone-beam computed tomography (CBCT) to assess the size and extent of the lesion.

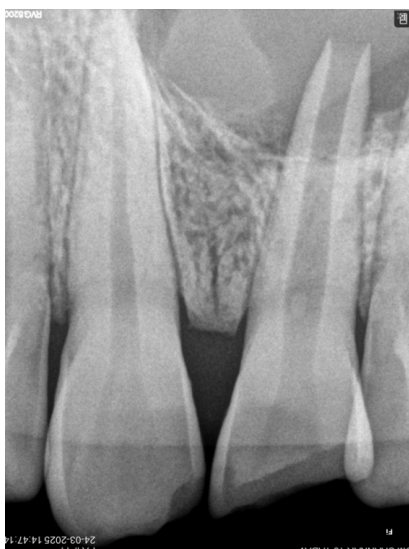Based on clinical and radiographic findings, the diagnosis was a necrotic pulp with chronic apical abscess with open apex. The treatment plan included root canal treatment of tooth 21, surgical enucleation of the cyst, apicoectomy with retrograde filling, thermoplasticized obturation, and subsequent esthetic rehabilitation with intracoronal bleaching.



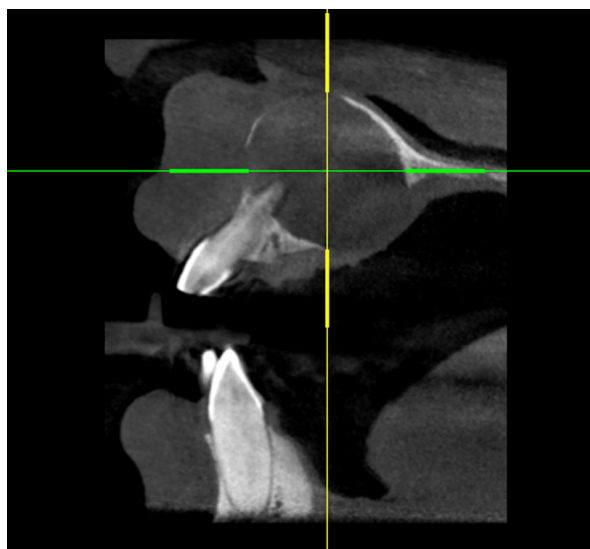
**Figure 1 : Preoperative photograph**



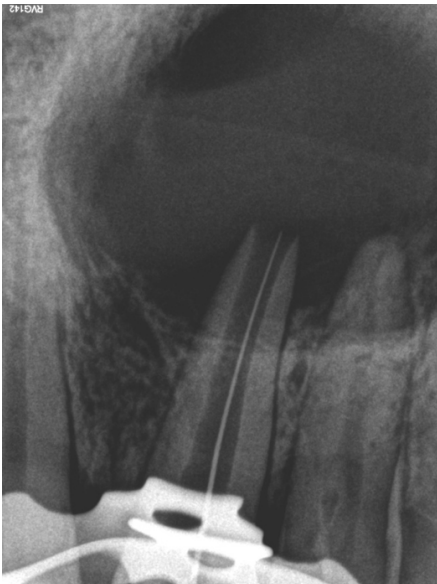**Figure 2: Palatal view**



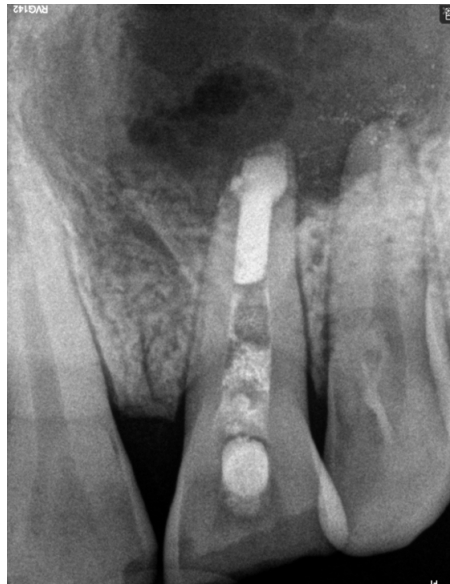**Figure 3 : Preoperative IOPA radiograph**



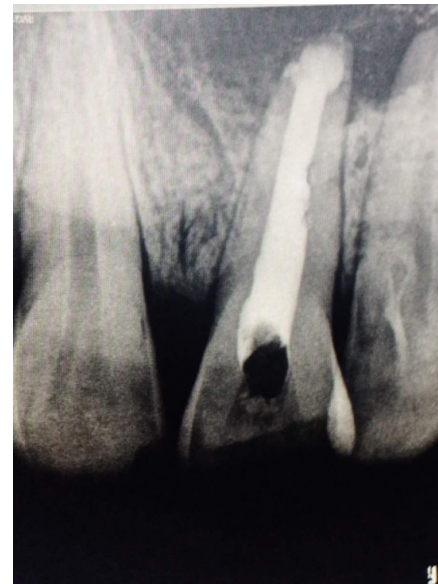**Figure 4: Cone beam computed tomography showing sagittal section (CBCT)**



**Figure 5: IOPAR of Working length determination**



**Figure 6: IOPAR showing retrograde filling**



**Figure 7 : IOPAR showing obturation with thermoplasticized guttapercha**

## CLINICAL PROCEDURE

Access opening was performed in relation to 21 and working length was verified radiographically. Using a K-file, the canal was shaped in a circumferential manner to an file size of upto no. #80.

The canal was irrigated copiously and calcium hydroxide intracanal medicament dressing was given.

However, there was continuous pus discharge from the canal even after multiple visits of dressing and hence surgical enucleation of cyst was approached.

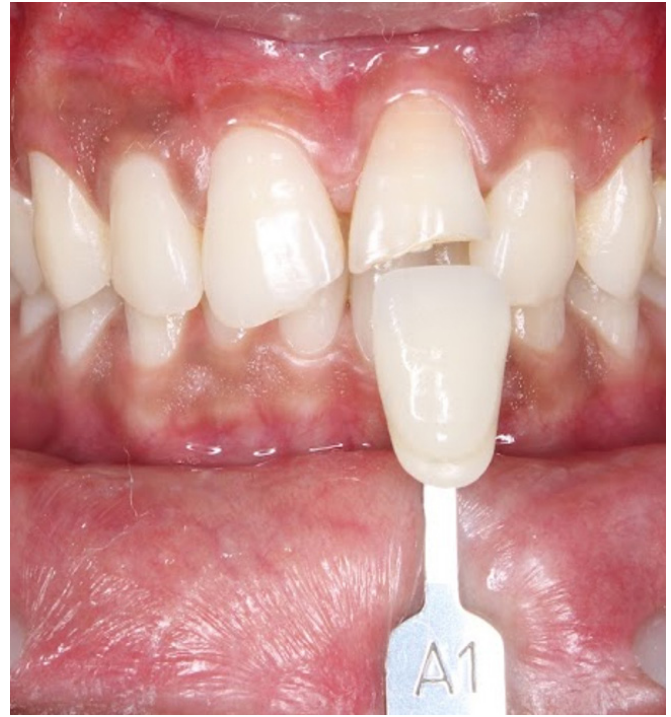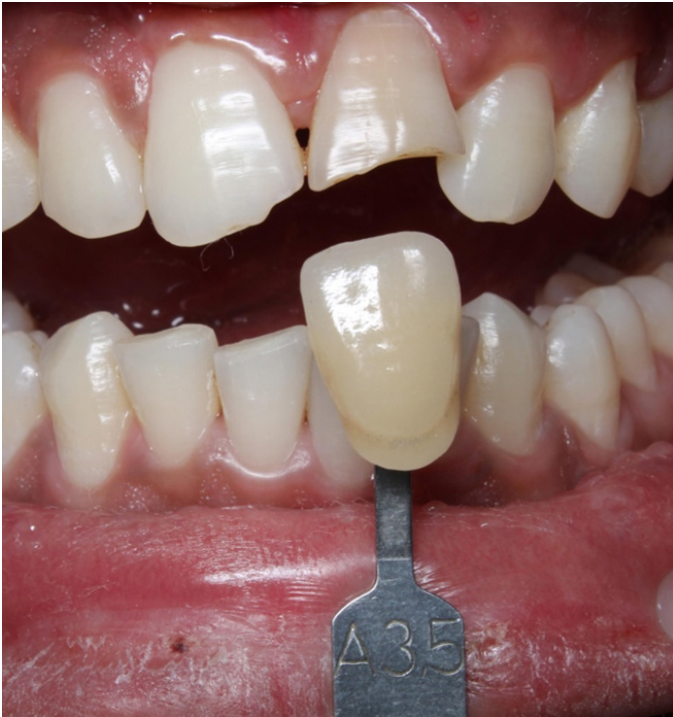Surgical enucleation was performed through buccal approach and sulcular incision was given in the labial region extending from distal of 12 to 24 , then two vertical incisions were given and full-thickness trapezoidal mucoperiosteal flap was reflected. Selective curettage and enucleation of cyst was done. Root end of involved teeth was resected, and the retrograde filling was done with Bio C Repair. Closure of flap was done with 3-0 black silk suture.

Stent was given to patient to support the palatal mucosa.

After suture removal and initial soft-tissue healing, root canal obturation of tooth 21 was completed using thermoplasticized guttapercha.

## NON-VITAL BLEACHING IN TOOTH 21

The bleaching procedure was initiated after one month of surgical healing and confirmation of asymptomatic status. First the access cavity was reopened and root canal filling material was removed to a depth of 2 mm below the cemento-enamel junction to provide a place for cervical seal material. A 2 mm thick light cured glass ionomer cement (GIC) barrier was placed over the canal filling. After the cervical seal area was dried, the bleaching material in the form of hydrogen peroxide gel 35% (Opalescence Endo, Ultradent Product Inc.,USA) was placed into the pulp chamber and was sealed with cotton pellet and glass ionomer cement. The patient was recalled every seven days to evaluate the change in shade.

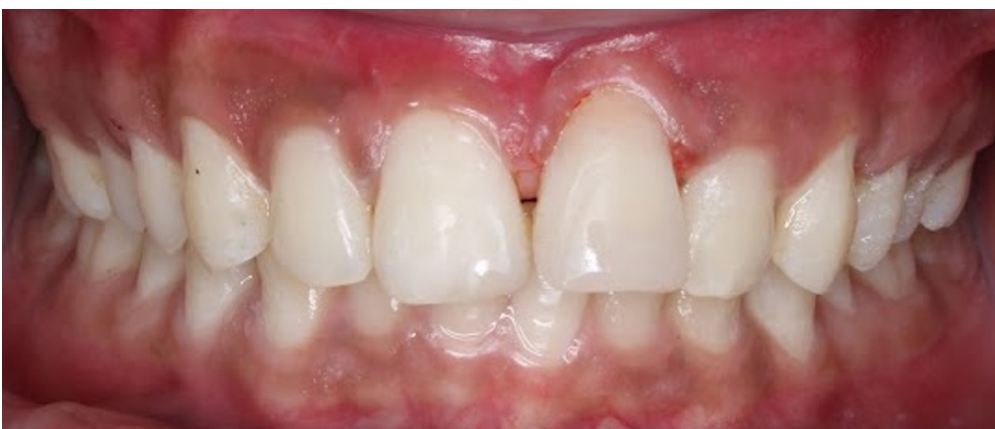

**Figure 8 & 9 : Showing two session of application of bleaching agent where the tooth discoloration shade changed from A3.5 to A1(Vitapan classical)**

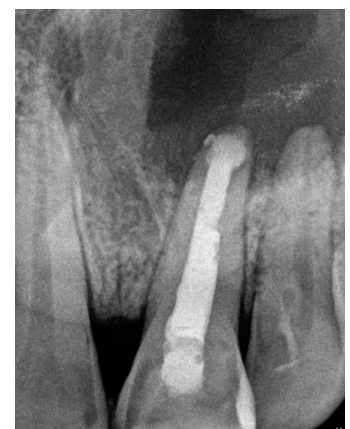After gaining the desired shade, the pulp chamber was thoroughly rinsed to remove all remnants of bleaching material and definitive restoration was done with composite after two weeks.

#### **DEFINITIVE RESTORATION**

The access cavity and fractured portion were etched, bonded, and restored with a nano-hybrid composite resin. Final finishing and polishing were performed to achieve optimal esthetics.



**Figure 10. Final composite restoration**



**Figure 11: IOPAR showing three month followup**

## DISCUSSION

Cyst is defined as a pathological cavity that is usually lined by epithelium and has a centrifugal, expansive mode of growth.<sup>6</sup> Among the cystic lesions of jaws, radicular cysts are most frequently seen, comprising 52% (Shear 1992) to 68% (Killy 1977) of all jaw cysts.<sup>6</sup> Trauma has been identified as one of the significant etiological factors associated with the development of radicular cysts.<sup>5</sup> In addition, persistent pulpal or periapical infection can stimulate cyst formation, progressing through well-recognized stages of initiation, cyst development and enlargement.<sup>6</sup>

In the present case, the patient had a history of trauma in the maxillary anterior region. These findings suggest that trauma could possibly be the etiology for pulpal necrosis, leading to the development of a radicular cyst. Radicular cysts are often asymptomatic. In the present case, patient was asymptomatic, however, a year ago noticed swelling along with pus discharge from gingiva. Based on clinical examination, the treatment plan included root canal treatment with respect to 21. Even after multiple sessions of intracanal medicament, canal showed pus drainage and also considering the large size of the lesion surgical enucleation and curettage was considered. Root end resection of 21 was carried out and retrograde filling with Bio C repair was done. After suture removal and initial soft tissue healing, obturation was carried out by thermoplasticized gutta-percha to obtain a three-dimensional and hermetic seal.

In the present case, the patient was comfortable throughout the follow-up period carried out at one week, one month, and three months with no clinical

signs and symptoms. The patient has been kept on further follow up.

In this case, nonvital bleaching was also performed for the discolored tooth 21 to improve the esthetics. The non-vital teeth discoloration usually results from intrinsic factors such as pulp necrosis or pulp hemorrhage leading to breakdown of pulp tissue producing iron or hemoglobin particles which deposit into the dentinal tubules, causing discoloration.<sup>7</sup> Opalescence Endo (ultradent TM, Utah, USA), a 35% hydrogen peroxide gel designed specifically for walking bleach method which has shown successful results, was used in the present case.<sup>8</sup> Nonvital bleaching is a noninvasive, simple, effective, and low-cost procedure, with good esthetic results, for the treatment of nonvital tooth discolorations.

Likewise, application of bleaching agent changed the discolored tooth shade from A3.5 to A1 in two sessions. A two-week delay was done for the final composite resin restoration. After the stabilization of the color, fractured tooth was finally restored with composite resin. The successful management of anterior teeth with open apices and periapical pathology requires a strategic, multidisciplinary approach that addresses both the biological and esthetic demand of the case. This case underscores the importance of individualized treatment planning and the integration of endodontic, surgical, and cosmetic approaches to restore the function, health, and esthetics of the tooth.

**Conflict of Interest:** None



## REFERENCES

1. Andreasen JO, Andreasen FM, Skeie A, et al. Effect of treatment delay upon pulp and periodontal healing of traumatic dental injuries: a review article. *Dent Traumatol*. 2002 Jun;18(3):116–128. [[PubMed](#) | [Full Text](#) | [DOI](#)]
2. Pawar AM, Kokate SR, Shah RA, et al. Management of a large periapical lesion using Biodentine™ as retrograde restoration with eighteen months evident follow-up. *J Conserv Dent*. 2013 Nov;16(6):573–575. [[PubMed](#) | [Full Text](#) | [DOI](#)]
3. Abusrewil SM, McLean W, Scott JA, et al. The use of bioceramics as root-end filling materials in periradicular surgery: a literature review. *Saudi Dent J*. 2018 Oct;30(4):273–282. [[PubMed](#) | [Full Text](#) | [DOI](#)]
4. Moradas M, Alvarez B, et al. Do thermoplastic materials improve the obturation of the root canal? Bibliographic review of the different techniques available in the market. *J Dent Health Oral Disord Ther*. 2018;9(1):00323. <https://medcraveonline.com/JDHODT/JDHODT-09-00323.pdf>
5. Gupta R, Bhagabati N, Jain G, et al. Management of a nonvital discolored tooth associated with radicular cyst: a multidisciplinary approach. *J Interdiscip Dent*. 2020;10(3):137–140. [https://journals.lww.com/joid/fulltext/2020/10030/management\\_of\\_a\\_nonvital\\_discolored\\_tooth.9.aspx](https://journals.lww.com/joid/fulltext/2020/10030/management_of_a_nonvital_discolored_tooth.9.aspx)
6. Kadam NS, Ataide Ide N, Raghava P, et al. Management of large radicular cysts by conservative surgical approach: a case report. *J Clin D*. 2014 Oct;8(10):ZD239–Z. [[PubMed](#) | [Full Text](#) | [DOI](#)]
7. Plotino G, Buono L, Grande NM, et al. Nonvital tooth bleaching: a review of the literature and clinical procedures. *J Endod*. 2008 Apr;34(4):394–407. [[PubMed](#) | [Full Text](#) | [DOI](#)]
8. Ozkocak I, Hekim M, Gokturk H, et al. Assessment of the efficiency of different bleaching agents on discolored teeth using image-processing methods. *Photodiagnosis Photodyn Ther*. 2020;31:101901. [[PubMed](#) | [Full Text](#) | [DOI](#)]