

Enhancing Physical Properties of Maxillary Complete Denture Using Metal Denture Base: A Case Report

Verma A¹, Joshi S², Joshi P³

¹ Resident. ² Professor, Prosthodontic Unit, Department of Dental Surgery

³ Consultant Prosthodontist, Dental Department

^{1,2} National Academy of Medical Sciences, Bir Hospital, Kathmandu, Nepal.

³ Nepal Police Hospital, Kathmandu, Nepal.

ABSTRACT

Several difficulties are encountered in providing a successful, single complete denture treatment opposing the natural dentition. This case report deals with the oral rehabilitation of completely edentulous maxillary arch opposing a natural dentition prosthetically by incorporating metal denture base in place of a conventional poly methyl methacrylate denture base material. Metal bases are used to enhance the physical properties of complete dentures and to combat the masticatory forces from natural dentition thus improving the longevity of the prosthetic replacement.

Keywords: metal denture base, maxillary complete denture, single complete denture

INTRODUCTION

Most of the patients become edentulous in one arch while retaining some or all of their natural teeth in the opposing arch. Several difficulties are encountered in providing a successful, single complete denture treatment.¹ Artificial dentures function like mechanical machines in an anatomic environment.² Single complete dentures may be opposed by (1) natural teeth (2) fixed restorations (3) a removable partial denture (4) an existing complete denture.¹ To maximize strength and to minimize weight the metal denture bases are commonly used.

The Poly Methyl Metha Acrylate (PMMA) as a denture base material are weak in mechanical properties and are susceptible to impact and fatigue failure. Reinforcement of conventional PMMA resin through incorporation of rubber inclusions and fibers has significantly enhanced the impact and flexural strength of material and its fatigue resistance. There are certain situations where a single denture opposes a full or partial complement of natural teeth or fixed restorations.

An unfavorable/irregular occlusal plane, heavy anterior contacts, and heavy masticatory forces directed into a virtually thin resin plate may collectively contribute to denture fracture. In such a situation, the choice of a cast metal base has been recommended as an effective alternative to resin bases.³

CASE REPORT

A 63-year-old male reported to the Department of Dental Surgery, Prosthodontic Unit, NAMS, with a chief complaint of fractured maxillary denture (Figure 1). Patient gave the history of multiple incidence of denture fracture. On intraoral examination, the patient was having complete edentulous maxillary arch and opposing natural dentition. The cause for repeated denture fracture may be due to excessive force exerted by the opposing natural dentition during function. The patient was philosophical (House classification).⁴ The metal maxillary denture was planned for this patient.

Correspondence: Dr. Anand Verma; e-mail: mailanandv@gmail.com

Case Report

PROCEDURE

The preliminary phases of metal denture base construction do not differ significantly from conventional resin-base techniques.

Impression of the lower natural teeth was made with an irreversible hydrocolloid impression material (Zelgan 2002, Dentsply) and the diagnostic cast was poured. Preliminary impression of the edentulous maxilla (Figure 2) was made with impression compound (Samit Impression Compound, Dento Kem, India) and plaster cast was poured for the fabrication of a special tray.

The peripheral tracing procedures were completed with green stick impression compound (DPI Pinnacle Tracing Sticks, Bombay, India) and the secondary impression was made with zinc oxide eugenol impression material (DPI Impression Paste, Bombay, India). Master cast was made with dental stone Type IV (Figure 3) and the mould of the same was made with reversible hydrocolloid (agar agar).

The refractory cast was then poured with phosphate bonded investment material (Gilvest Investment, Germany). On the refractory cast the denture base pattern wax was adapted and the sprues were attached and invested (Figure 4). The denture base was casted with cobalt chromium alloy (BEGO, Germany) (Figure 5). The metal denture base was designed to cover the palate and residual ridges with retentive mesh extending on the ridges and the posterior palatal seal area for mechanical retention of acrylic resin and teeth to the metal.

After facebow transfer, jaw relation was established and transferred on the semi adjustable articulator (Hanau H2) (Figure 6 and 7). The teeth arrangement was done to achieve bilateral contacts in centric occlusion (Figure. 8) and gliding contact during eccentric movements as guided by the lower natural dentition, esthetics and phonetics. A trial of waxed up maxillary complete denture was made followed by acrylization of the complete denture (Figure 9) with heat polymerized acrylic resin. The interferences in denture were eliminated and denture insertion (Figure 10) was done. Post

insertion instructions were given to the patient regarding its maintenance and hygiene.

DISCUSSION

One of the common clinical situations involving a single denture is that of a complete upper denture and lower natural dentition. When a complete denture is opposed by natural teeth, it will require some degree of contouring to provide a harmonious occlusion. The reasons for such alteration is mainly due to (1) Unfavorable inclination of the occlusal plane (2) malposition individual teeth which have assumed positions resulting excessively steep cuspal inclinations, and (3) too wide buccolingual width of the natural teeth.¹ There might be occlusal stress on the maxillary denture and the underlying edentulous tissue due to forces from teeth and musculature and opposing natural teeth. The position of the mandibular teeth, which are improperly aligned may also avoid achievement of bilateral balance for stability and lead to flexure of the denture bases.⁵ The midline fracture in a denture is often a result of flexural fatigue and may also be accompanied by deep labial notch.

Polymers are the dominant material for the fabrication of denture bases.⁶ Poly Methyl Metha Acrylate denture bases have good mechanical, biological and esthetic properties. The impact and fatigue strength of PMMA are not entirely satisfactory thus may fail when there is excessive parafunctional and / or functional forces.⁷ There are instances in which these PMMA bases fail because of poor denture base adaptation. In those situations metal alloys have been used to strengthen the bases and prevent fracture.^{8,9} Besides rigidity and fracture resistance these metal bases have several other advantages like excellent strength to volume ratio, good adaptation to the supporting tissues, enhanced plaque control, high thermal conductivity, very little dimensional changes in time through fluid absorption.^{5,10}

The metal bases provide an important alternative dental service for edentulous HIV-positive patients or other patients with higher incidences of fungal infections. A relatively thin

Case Report

metal base is cast to contact the tissue bearing surface, covering the whole palate and providing superior fit and comfort to the patient.³ The metal denture bases are good thermal conductors and are less bulky. There would be no propagation of crack from the deep labial notch as well. The PMMA in the posterior palatal seal would allow for relining of the denture in the long run.

The resin-metal junction must be carefully positioned and sculpted to ensure proper palatal contours during denture fabrication. Failure to achieve unobtrusive palatal contours may produce noticeable changes in phonation.¹¹

Daily hygiene for a removable denture should include brushing, immersion in disinfectant solutions for biofilm removal and decontamination. Metal alloys can corrode or stain as a result of surface contact with the chlorine or oxygen present in some commercial cleansers.¹² The commercial denture cleansing tablet and the commercial bleach should not be limitlessly used on dentures with metal components, because they caused clinically significant reflectance changes on the surface of the alloy after 30 days.¹³

The major disadvantages associated with metal denture bases include increased cost, difficulty in fabrication, compromised esthetic qualities, and inability to rebase such prostheses.¹⁰ Nevertheless, they may be indicated when polymer-based systems fail to provide acceptable physical properties. The fabrication of metal denture bases is not complicated and not cost prohibitive when base metal alloys are used.

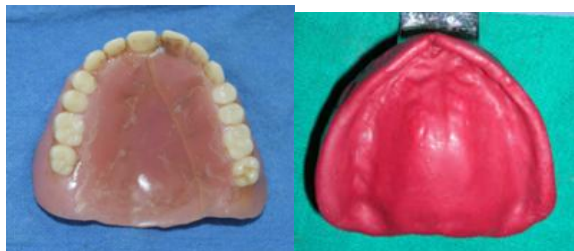

Figure 1: Maxillary denture with multiple fracture lines

Figure 2: Preliminary impression with impression compound

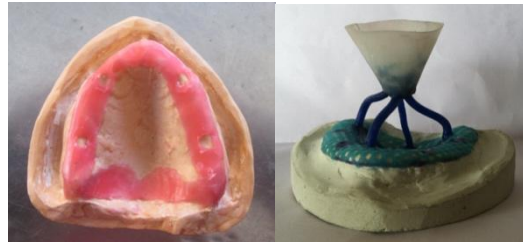

Figure 3: Master cast with relief wax

Figure 4: Denture base pattern wax with the sprues

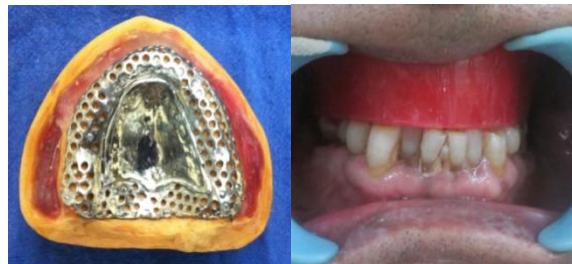

Figure 5: Cobalt chromium alloy denture base

Figure 6: Jaw relation recording

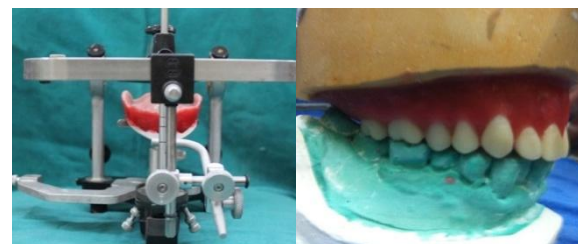


Figure 7: Direct mounting

Figure 8: Teeth arrangement

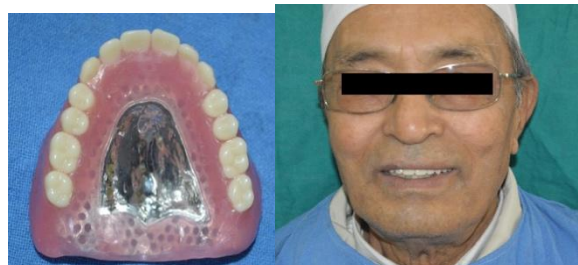

Figure 9: Finished denture

Figure 10: Post-operative photograph

CONCLUSION

The combination of maxillary metal base, opposing natural dentition provides great comfort and satisfaction to the patient. The metal denture base strongly resists the catastrophic failure and flexural fatigue thus combats the masticatory forces from natural dentition improving the longevity of the prosthetic replacement. Methacrylate resin retains the denture teeth and provides buccal and labial flanges that enhance the esthetic quality of denture and compensates for missing soft tissues.

REFERENCE

1. Ellinger CW, Jack H. Rayson, Davis Henderson. Single complete denture. *J Prosthet Dent*. 1971;26(1):4-10.
2. French FA. The problem of building satisfactory dentures. *J Prosthet Dent*. 1954;4: 769-81.
3. Zarb, Hobkirk, Eckert, Jacob. *Prosthodontic treatment for edentulous patients: complete denture and implant-supported prosthesis*. 13th ed. Mosby, 2013, p149.
4. Stansbury CB. Single denture construction against a nonmodified natural dentition. *J Prosthet Dent*. 1951; 1(6):692-99.
5. Koper A. The maxillary complete denture opposing natural teeth : problems and some solutions. *J Prosthet Dent* 1987; 57(6):704-7.
6. Craig RG. *Restorative dental materials*. 9th ed. St Louis; Mosby Year Book, Inc. 1993:502-50.
7. Ohkubo C. et al. Comparative study of maxillary complete dentures constructed of metal base and metal structure framework. *Journal of oral rehabilitation*. 2001;28: 1 49-56.
8. Grunewald AH. Gold base lower dentures. *J Prosthet Dent* 1964;14:432-41.
9. Lundquist DO. An aluminum alloy as a denture-base material. *J Prosthet Dent* 1963;13:102-10.
10. Faber BL. Lower cast metal base denture. *J Prosthet Dent*. 1957;7: 51-4.
11. Patrick A. Mattie, Rodney D. Phoenix. A Precise design and fabrication method for metal base maxillary complete dentures. *J Prosthet Dent* , 1996;76:496-9.
12. Mc Gowan et al. Effects sodium hypochlorite on denture base metals during immersion for short term sterilization. *J Prosthet Dent* 1988;60:212-8.
13. Keyf F et al. Comparison of Effects of Bleach and Cleansing Tablet on Reflectance and Surface Changes of a Dental Alloy Used for Removable Partial Dentures. *J Biomater Appl* July 2003 18: 5-14.